



Recommendations for interpretation of 12-lead electrocardiogram in the athlete

Domenico Corrado^{1*}, Antonio Pelliccia², Hein Heidbuchel³, Sanjay Sharma⁴, Mark Link⁵, Cristina Basso⁶, Alessandro Biffi², Gianfranco Buja¹, Pietro Delise⁷, Ihor Gussac⁸, Aris Anastasakis⁹, Mats Borjesson¹⁰, Hans Halvor Bjørnstad¹¹, François Carrè¹², Asterios Deligiannis¹³, Dorian Dugmore¹⁴, Robert Fagard³, Jan Hoogsteen¹⁵, Klaus P. Mellwig¹⁶, Nicole Panhuyzen-Goedkoop¹⁷, Erik Solberg¹⁸, Luc Vanhees³, Jonathan Drezner¹⁹, N.A. Mark Estes, III⁵, Sabino Iliceto¹, Barry J. Maron²⁰, Roberto Peidro²¹, Peter J. Schwartz²², Ricardo Stein²³, Gaetano Thiene⁶, Paolo Zeppilli²⁴, and William J. McKenna²⁵ On behalf of the Sections of Sports Cardiology of the European Association of Cardiovascular Prevention and Rehabilitation; and the Working Group of Myocardial and Pericardial Disease of the European Society of Cardiology

¹Department of Cardiac, Thoracic and Vascular Sciences, University of Padua Medical School, Via Giustiniani,2, Padova 35121, Italy; ²Institute for Sports Sciences, Rome, Italy; ³Cardiovascular Rehabilitation Unit, KU Leuven, Leuven, Belgium; ⁴King's College Hospital, London, UK; ⁵New England Medical Center, Boston, MA, USA; ⁶Department of Medical-Diagnostic Sciences, University of Padua, Padua, Italy; ⁷Civil Hospital, Conegliano, Italy; ⁸University of Medicine and Dentistry, RWJ Medical School, New Brunswick, NJ, USA; ⁹Division of Inherited Cardiovascular Diseases, University of Athens, Greece; ¹⁰Department of Medicine, Sahlgrenska University Hospital/Östra, Gothenburg, Sweden; ¹¹Department Heart Disease, Haukeland University Hospital, Bergen, Norway; ¹²Sport Medicine, University of Rennes, Rennes, France; ¹³Sports Medicine, Aristotle University, Thessaloniki, Greece; ¹⁴Wellness Medical Center, Stockport, UK; ¹⁵Department of Cardiology, Maxima Medical Centre, Veldhoven, Netherlands; ¹⁶Heart Center NRW, University Hospital, Bad Oeynhausen, Germany; ¹⁷Department Cardiology, Nijmegen, The Netherlands; ¹⁸Klinikk Ullevål Sykehus, Oslo, Norway; ¹⁹Department of Family Medicine, University of Washington, Seattle, WA, USA; ²⁰Hypertrophic Cardiomyopathy Center, Minneapolis Heart Institute Foundation, Minneapolis, MN, USA; ²¹Favaloro Foundation, Buenos Aires, Argentina; ²²Department of Cardiology, Fondazione IRCCS Policlinico, San Matteo, Pavia; ²³Exercise Pathophysiology Research Laboratory, Hospital de Clinicas Porto Alegre, Porto Alegre, Brazil; ²⁴Sports Medicine Department, Institute of Internal Medicine and Geriatrics, Catholic University of Sacred Heart, Rome, Italy; and ²⁵The Heart Hospital, University College of London, London, UK

Received 20 July 2009; revised 22 September 2009; accepted 4 October 2009

Cardiovascular remodelling in the conditioned athlete is frequently associated with physiological ECG changes. Abnormalities, however, may be detected which represent expression of an underlying heart disease that puts the athlete at risk of arrhythmic cardiac arrest during sports. It is mandatory that ECG changes resulting from intensive physical training are distinguished from abnormalities which reflect a potential cardiac pathology. The present article represents the consensus statement of an international panel of cardiologists and sports medical physicians with expertise in the fields of electrocardiography, imaging, inherited cardiovascular disease, cardiovascular pathology, and management of young competitive athletes. The document provides cardiologists and sports medical physicians with a *modern* approach to correct interpretation of 12-lead ECG in the athlete and emerging understanding of incomplete penetrance of inherited cardiovascular disease. When the ECG of an athlete is examined, the main objective is to distinguish between physiological patterns that should cause no alarm and those that require action and/or additional testing to exclude (or confirm) the suspicion of an underlying cardiovascular condition carrying the risk of sudden death during sports. The aim of the present position paper is to provide a framework for this distinction. For every ECG abnormality, the document focuses on the ensuing clinical work-up required for differential diagnosis and clinical assessment. When appropriate the referral options for risk stratification and cardiovascular management of the athlete are briefly addressed.

Keywords

Athlete's heart • Cardiomyopathy • Electrocardiogram • Ion-channel disease • Sudden death • Ventricular fibrillation • Ventricular tachycardia

* Corresponding author. Tel: +39 49 821 2458, Fax: +39 49 821 2309, Email: domenico.corrado@unipd.it

Introduction

Regular sports participation is encouraged by the medical community as part of cardiovascular prevention measures, because it improves fitness and reduces cardiovascular morbidity and mortality worldwide.^{1,2} A large proportion of the young population participates in competitive or recreational sports activity. The 12-lead electrocardiogram (ECG) is an established tool in the evaluation of athletes, providing important diagnostic and prognostic information on a variety of cardiovascular diseases which are associated with an increased risk of sudden cardiac death (SCD) during sports. Physicians are frequently asked to interpret an ECG in the setting of cardiovascular evaluation of athletes. Standard criteria for defining the limits of normal (or variation of normal) ECG in the athlete remain to be determined. The interpretation of the athlete's ECG is often left to personal experience and usually made according to traditional ECG criteria used in the general (non-athletic) population.

Electrocardiogram changes in athletes are common and usually reflect structural and electrical remodelling of the heart as an adaptation to regular physical training (athlete's heart).^{3–10} However, abnormalities of athlete's ECG may be an expression of an underlying heart disease which carries a risk of SCD during sport.^{11–13} It is important that ECG abnormalities resulting from intensive physical training and those potentially associated with an increased cardiovascular risk are correctly distinguished.^{14–17}

Errors in differentiating between physiological and pathological ECG abnormalities may have serious consequences. Athletes may undergo expensive diagnostic work-up or may be unnecessarily disqualified from competition for changes that fall within the normal range for athletes. This is of particular relevance for professional athletes in whom disqualification from competitive sports has significant financial and psychological consequences. Alternatively, signs of potentially lethal cardiovascular disorders may be misinterpreted as normal variants of an athlete's ECG. A correct evaluation of 12-lead ECG patterns in the athlete and appropriate subsequent action has the potential to increase efficacy, accuracy, and cost-effectiveness of athlete's cardiovascular evaluation.^{17–21}

Some consider that physiological ECG changes overlap significantly with ECG abnormalities seen in the cardiovascular diseases which cause SCD in the young.^{14–16} The ECG has therefore been considered a non-specific and non-cost-effective tool for cardiovascular evaluation of athletes because of a presumed high level of false-positive results. This concept was based on few studies of small and selected series of highly trained athletes from a limited number of sports disciplines. The 25-year Italian experience with universal pre-participation screening has offered the unique opportunity to investigate ECG changes in large cohorts of athletes, engaged in a broad variety of sports activities with different and well-characterized levels of training and fitness.^{22–25} The currently available data allow an accurate redefinition of the spectrum of athlete's ECG patterns and raise the need for a revision of accuracy, utility, and cost-benefit analysis of the use of ECG in the cardiovascular evaluation of the athlete. In addition, there is growing experience of early and incomplete disease expression of the inherited cardiomyopathies and

arrhythmias which usually have ECG changes as their initial presentation.^{26,27}

The present document is endorsed by the Sections of Sports Cardiology and Exercise Physiology of the European Association of Cardiovascular Prevention and Rehabilitation and by the Working Group on Myocardial and Pericardial diseases of the European Society of Cardiology and represents the position statement of an international panel of cardiologists and sports medical doctors with expertise in the field of cardiovascular evaluation of young competitive athletes. The article provides a *modern* approach to interpretation of 12-lead ECG in the athlete based on recently published new findings. The target audience are primarily sports medical doctors, sports cardiologists, and team physicians. The main objective is to differentiate between physiological adaptive ECG changes and pathological ECG abnormalities, with the aim to prevent adaptive changes in the athlete being erroneously attributed to heart disease, or signs of life-threatening cardiovascular conditions being dismissed as normal variants of athlete's heart. Because only pathological ECG abnormalities cause alarm and require action with additional testing to exclude (or confirm) the suspect of a lethal cardiovascular disorder, appropriate interpretation of an athlete's ECG also results in a considerable cost savings in the context of a population-based pre-participation screening program.¹⁷

The document provides *guided* clinical evaluation of the athletes with ECG abnormalities. For every ECG abnormality, the document focuses on the recommended clinical work-up for differential diagnosis and clinical assessment. When indicated the referral options for risk stratification and cardiovascular management are briefly addressed, although for more detailed and elaborated recommendations concerning eligibility for sports participation we refer to other specific guidelines.^{28–32} The document is also aimed to update general cardiologists and sports medical physicians with the clinically relevant information which can be obtained from ECG in the athlete.

Physiological vs. potentially malignant electrocardiogram changes

The athlete's ECG changes are divided into two groups: common and training-related (Group 1) or uncommon and training-unrelated (Group 2). This classification is based on prevalence, relation to exercise training, association with an increased cardiovascular risk, and need for further clinical investigation to confirm (or exclude) an underlying cardiovascular disease (Table 1).

Trained athletes commonly (up to 80%) show ECG changes such as sinus bradycardia, first-degree atrioventricular (AV) block, and early repolarization, which result from physiological adaptation of the cardiac autonomic nervous system to athletic conditioning, e.g. increased vagal tone and/or withdrawal of sympathetic activity. The ECGs of trained athletes often exhibit pure voltage criteria (i.e. based only on QRS amplitude measurements) for left ventricular (LV) hypertrophy that reflect the physiological

Table 1 Classification of abnormalities of the athlete's electrocardiogram

Group 1: common and training-related ECG changes	Group 2: uncommon and training-unrelated ECG changes
Sinus bradycardia	T-wave inversion
First-degree AV block	ST-segment depression
Incomplete RBBB	Pathological Q-waves
Early repolarization	Left atrial enlargement
Isolated QRS voltage criteria for left ventricular hypertrophy	Left-axis deviation/left anterior hemiblock
	Right-axis deviation/left posterior hemiblock
	Right ventricular hypertrophy
	Ventricular pre-excitation
	Complete LBBB or RBBB
	Long- or short-QT interval
	Brugada-like early repolarization

RBBB, right bundle branch block; LBBB, left bundle branch block.

LV remodelling with increased LV wall thickness and chamber size.^{7–9,14–17,24,25,33}

These physiological ECG changes should be clearly separated from uncommon (<5%) and training-unrelated ECG patterns such as ST-T repolarization abnormalities, pathological Q-waves, left-axis deviation, intraventricular conduction defects, ventricular pre-excitation, long and short QT interval and Brugada-like repolarization changes which may be the expression of underlying cardiovascular disorders, notably inherited cardiomyopathies or ion-channel diseases which may predispose to SCD.^{14–17}

This classification of ECG abnormalities has potential favourable effects on the athlete's cardiovascular management including clinical diagnosis, risk stratification, and cost savings. Common ECG changes due to cardiac adaptation to physical exertion (Group 1) should not cause alarm and the athlete should be allowed to participate in competitive sports without additional evaluation. Hence, in the absence of positive family history, symptoms or abnormal physical findings further diagnostic work-up is only needed for the subset of athletes with uncommon and not sports-related ECG changes, which potentially reflect an underlying heart disease with an increased risk of SCD (Group 2).

Common and training-related electrocardiogram changes

The extent of cardiac morphological and electrical changes in trained athletes varies with the athlete's gender, race, level-of-fitness, and type of sport.^{24,25,34–37} Physiological ECG abnormalities are more prevalent and significant in male athletes and athletes of African/Caribbean descent, in whom genetic/ethnic predisposing factors account for a more prominent cardiovascular remodelling, either structural or neuroautonomic, in response to physical training and competition.^{24,34,35} In this

regard, genotype and different polymorphisms of the angiotensin-converting enzyme or angiotensinogen genes have been reported to result in different phenotypic expression in athletes' hearts.^{36,37} Unlike male athletes who most commonly show abnormal ECG patterns, female athletes usually have normal or virtually normal ECGs.²⁴

The higher prevalence of normal ECG patterns in female athletes is likely due to several factors, including the mild morphological LV changes induced by training in women and their lower participation rates in certain disciplines (such as rowing/canoeing) that have a substantial impact on ECG pattern.²⁴ Black athletes have more prevalent and pronounced ECG changes, including voltage criteria for LV hypertrophy and early repolarization changes which reflect the race-related greater magnitude of LV hypertrophy and/or increased vagal sensitivity.^{34,35} Basavarajaiah *et al.* reported that approximately one-fifth of black athletes exhibit LV wall thickness >12 mm (compared with just 4% of white athletes) and 3% of black athletes have substantial increase of LV thickness (>15 mm).³⁵

Level and duration of training or competition, aerobic capacity and type of sports activity play a significant role as well. Participation in sports that require high endurance, such as cycling, cross-country skiing, and rowing/canoeing has been shown to be significantly associated with a higher rate and greater extent of physiological ECG changes such as sinus bradycardia and increase of QRS voltages compared with participation in sports that require more strength and speed and relatively less endurance.²⁴ This seems to be related to the large cardiac output acquired during endurance training, resulting in considerable cardiac remodelling including increase in LV cardiac dimension and wall thickness.³⁸ As a corollary, to be considered as a physiological expression of the athlete's heart, ECG changes such as sinus bradycardia, early repolarization pattern or increased QRS voltages should be consistent with the gender, age, and race as well as appropriate to the level of training and type of sports. Moreover, these ECG abnormalities should be interpreted in light of family background, personal history with review of symptoms, and physical examination of the athlete. In the presence of a positive family history, symptoms or abnormal physical findings, otherwise physiological ECG changes may become clinically relevant and require clinical work-up to exclude a pathological basis.

Sinus bradycardia/arrhythmia

Resting sinus bradycardia, as defined by a heart rate less than 60 b.p.m., is common in athletes, depending on the type of sport and the level of training/competition.^{39–41} Heart rate is generally lower in endurance sports such as long-distance running, and inversely correlate with the level-of-fitness of the individual athlete. In highly trained athletes, marked bradycardia less than 30 b.p.m. and asymptomatic sinus pauses greater than 2 s are not uncommon during 24 h ECG, particularly during sleep. Escape junctional beats or rhythms are recorded in athletes with marked bradycardia and result in functional AV dissociation. Sinus bradycardia is easily overcome with exercise, suggesting that high vagal tone causes slowing of the sino-atrial node. However, it is noteworthy that chemically denervated hearts in athletes have significantly lower intrinsic heart rates than those of sedentary controls: this suggests that sinus

pacemaker cells are influenced by athletic conditioning independent of neural input.⁴²

Sinus arrhythmia is also reported with widely varying frequency, from 13 to 69%.^{39–41,43} Such variations are explained by the individual athlete's autonomic state and level-of-fitness, as well as by the definition of sinus arrhythmia used by the various authors. Like bradycardia, sinus arrhythmia is believed to reflect an increased vagal tone.

Recommendation

Bradycardia is the result of a physiological adaptive change of the autonomic nervous system and reflects the level of athletic conditioning. Only profound sinus bradycardia and/or marked sinus arrhythmia (heart rate less than 30 b.p.m. and/or pauses ≥ 3 s during wake hours) need to be distinguished from sinus node disease. Sino-atrial node dysfunction can be reasonably excluded by demonstrating that: (i) symptoms such as dizziness or syncope are absent; (ii) heart rate normalizes during exercise, sympathetic manoeuvres or drugs, with preservation of maximal heart rate, and (iii) bradycardia reverses with training reduction or discontinuation.

Atrioventricular block

First-degree AV block and Mobitz Type I (Wenkebach) second-degree AV block are common in trained athletes, being present in ~ 35 and 10% of athlete's ECGs, respectively.^{43–45} As with sinus bradycardia, AV conduction slowing and block are mediated by increased parasympathetic tone and/or decreased resting sympathetic tone. Second-degree Mobitz Type II and third-degree heart block are rare in the athlete and caution should be used in accepting these findings as normal adaptive changes to training.^{30,43}

Recommendation

Resolution of (asymptomatic) first- or second-degree AV block with hyperventilation or exercise confirms its functional origin and excludes any pathological significance. In athletes with Type II second-degree (Mobitz Type II) and third-degree AV block, a careful diagnostic evaluation is mandatory and pacemaker implantation may be indicated.

Isolated increase of QRS voltages

Intensive athletic conditioning is associated with morphological cardiac changes, including increased cavity dimensions, wall thickness, and ventricular mass, which are reflected on the 12-lead ECG.^{3–6} Physiological LV hypertrophy in trained athletes usually manifests as an isolated increase of QRS amplitude, with normal QRS axis, normal atrial and ventricular activation patterns, and normal ST-segment T-wave repolarization.^{14,24,33,41,43,46–48} A high prevalence of ECGs that fulfil Sokolow–Lyon voltage criteria for LV hypertrophy has been consistently reported in trained athletes.^{24,33,45} Pelliccia et al.²⁴ assessed the prevalence and type of ECG abnormalities in 1005 elite Italian athletes, aged 24 ± 6 years, 75% male who participated in 38 sporting disciplines. They correlated ECG changes with cardiac morphology assessed by echocardiography. The ECG was labelled as 'abnormal' in 402 athletes (40%), however, an isolated increase of QRS voltage accounted for $\sim 60\%$ of such changes. The prevalence of voltage

LV hypertrophy differed with respect to the type of sports discipline and was more frequent in athletes engaged in endurance disciplines, such as cycling, cross-country skiing, and rowing/canoeing. Increased QRS voltage was also associated with male gender and increased cardiac dimensions and wall thickness. No athletes with isolated increase of QRS voltages had evidence of structural heart diseases including hypertrophic cardiomyopathy (HCM).

Non-voltage ECG criteria for LV hypertrophy such as atrial enlargement, left-axis deviation, a 'strain' pattern of repolarization, and delayed intrinsicoid deflection (which are incorporated into the Romhilt-Estes point score system) are not usually seen in athletes.^{24,25,33} These ECG abnormalities raise suspicion for underlying cardiac pathology e.g. HCM, aortic valve disease, hypertension. On the other hand, an *isolated* increase of QRS voltages (Sokolow–Lyon or Cornell criteria) is a very uncommon finding in HCM patients (see Non-voltage criteria for LV hypertrophy section).

Recommendation

Athletes who show pure QRS voltage criteria for LV hypertrophy on 12-lead ECG do not require systematic echocardiographic evaluation, unless they have relevant symptoms, a family history of cardiovascular diseases, and/or SCD or non-voltage ECG criteria suggesting pathological LV hypertrophy.

Incomplete right bundle branch block

The prevalence of incomplete right bundle branch block (RBBB) (QRS duration < 120 ms) has been estimated to range from 35 to 50% in athletes compared with less than 10% in young, healthy controls.^{24,47,49–52} The ECG pattern is more often noted in athletes engaged in endurance sports, with a striking male preponderance. It has been suggested that the right ventricular (RV) conduction delay is not within the specialized conduction system, but is caused by the enlarged RV cavity size/increased cardiac muscle mass and the resultant increased conduction time.⁴⁹ The RBBB morphology has been shown to be reversible with deconditioning.⁵²

Recommendation

Incomplete RBBB does not require further evaluation in the presence of a negative family/personal history and physical examination. Because incomplete RBBB is a typical ECG finding in patients with an 'ostium secundum' atrial septal defect, symptoms and a fixed split of the second heart sound on auscultation should be excluded.

'Typical' incomplete RBBB is uncommon in patients with arrhythmogenic RV cardiomyopathy (ARVC).⁵³ Arrhythmogenic RV cardiomyopathy should be suspected when the pattern of incomplete RBBB is associated with T-wave inversion extending beyond V2 to include leads V3 and V4 or in the presence of premature ventricular beats with a left bundle branch block (LBBB) morphology.

In some cases, incomplete RBBB should be differentiated from a Brugada-ECG which is characterized by a slow, positive deflection at the R-ST junction ('J-wave'), which is most evident in leads V1 and V2, with minimal or no reciprocal changes in other leads⁵⁴ (Figure 1). Unlike the R'-wave seen in RBBB, the J-wave seen in

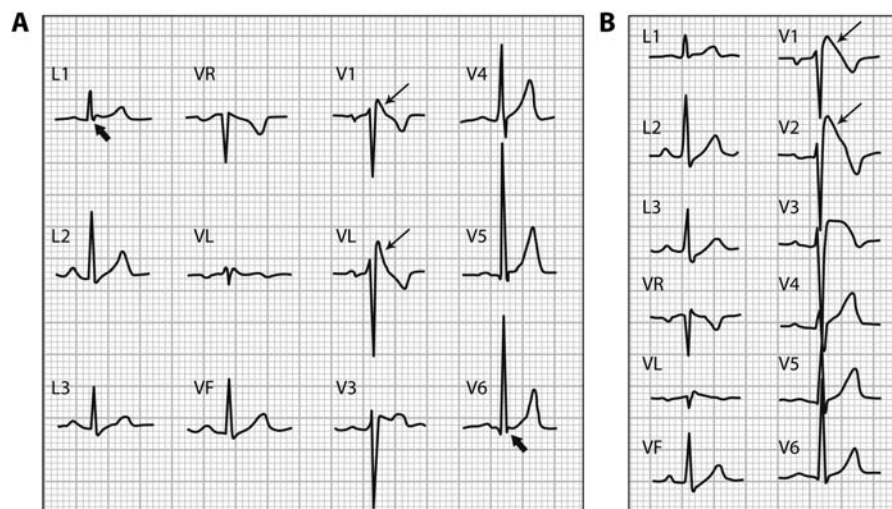


Figure 1 (A) Borderline Brugada-ECG pattern mimicking incomplete RBBB. Unlike the 'R-wave' of RBBB, the 'J-wave' (arrows) of Brugada-ECG is confined to right precordial leads (V1 and V2) without reciprocal 'S-wave' (of comparable voltage and duration) in the leads L1 and V6 (arrowhead). (B) In this case, definitive diagnosis of Brugada ECG was achieved by a drug challenge with sodium channel blockers which unmasked diagnostic 'coved type' (arrows) pattern (V1 and V2).

Brugada syndrome does not indicate delayed RV activation, but reflects early repolarization with J-point elevation and a high take-off ST-segment. The downsloping ST-segment is followed by a negative ('coved' type) or a positive ('saddle-back' type) T-wave. In typical RBBB, the R'-wave recorded in V1 and V2 is associated with a reciprocal S-wave in leads I and V6, and there is no ST-segment elevation in the right precordial leads.⁵⁵ Differential diagnosis may require a drug challenge with sodium channel blockers (Figure 1).

Early repolarization

Early repolarization has traditionally been regarded as an idiopathic and benign ECG phenomenon, with an estimated prevalence in healthy young individuals of 1–2%, and a clear male preponderance.^{56–59} The early repolarization ECG pattern is the rule rather than the exception among highly trained athletes, in whom it is observed in 50–80% of resting ECGs.^{60,61} The early repolarization ECG shows elevation of the QRS–ST junction (J-point) of at least 0.1 mV from baseline, associated with notching or slurring of the terminal QRS complex which may vary in location, morphology, and degree.^{58,59} These changes often are localized in precordial leads, with the greatest ST-segment elevation in mid-to-lateral leads (V3–V4), but maximal ST-segment displacement may also be seen in lateral leads (V5, V6, I, and aVL), inferiorly (II, III, and aVF), or anteriorly (V2–V3).^{59,61,62} The most common morphological pattern seen in Caucasians is an elevated ST-segment with an upward concavity, ending in a positive ('peaked and tall') T-wave (Figure 2A). In athletes of African-Caribbean descent, however, the morphology is often different with an elevated ST-segment with an upward convexity, followed by a negative T-wave (Figure 2B) in V2–V4. This pattern, with the 'domed' morphology of the elevated ST-segment requires

differentiation from the Brugada-ECG (see Brugada-like ECG abnormalities section).^{61,62}

The magnitude of ST-segment elevation is characteristically modulated by autonomic influences and heart rate changes which explain the dynamic nature of the ECG abnormalities with waxing and waning of the ST-segment and T-wave over time.^{56–59} Slowing of heart rate exaggerates ST-segment elevation, whereas sinus tachycardia occurring during exercise or after isoproterenol reduces and often eliminates early repolarization changes. Early repolarization in athletes reflects the development of a training-related hypervagotonia, and ECG abnormalities are a reversible phenomenon which reduces or disappears with deconditioning.

Recently, isolated changes of early repolarization in inferior and/or lateral leads with terminal QRS slurring has been reported in patients with idiopathic ventricular fibrillation.⁶³ The study was a retrospective analysis of a selected cohort with episodes of short coupled rapid/polymorphic ventricular tachycardia or ventricular fibrillation leading to syncope or cardiac arrest. The available data do not support the view that in the general population of asymptomatic young individuals or athletes this ECG pattern is predictive of an increased risk of malignant ventricular arrhythmias.

Recommendation

Early repolarization is a physiological and benign ECG pattern in the general population of young people and athletes and does not require further clinical evaluation.

In athletes of African/Caribbean origin the presence of ST-segment elevation followed by T-wave inversion confined to leads V2–V4 is consistent with a physiological early repolarization ECG pattern (Figure 3A). Such adaptive ST-segment and T-wave repolarization changes characteristically normalize during exercise or adrenergic stimulation.

In trained athletes, right precordial ST-T changes of early repolarization show typical features which permit differentiation from

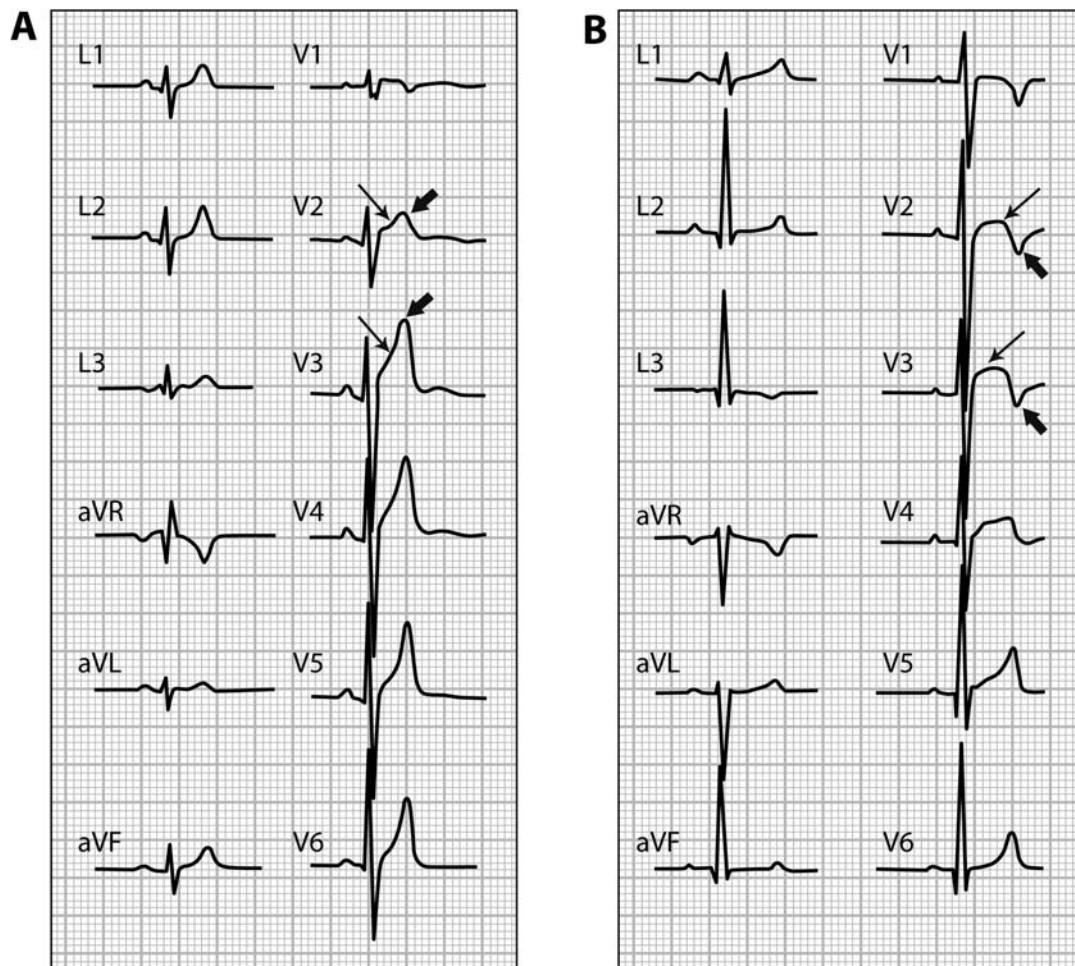


Figure 2 Different patterns of precordial early repolarization in two healthy athletes. (A) ST-segment elevation with upward concavity (arrows), followed by a positive T-wave (arrowheads). (B) ST-segment elevation with upward convexity (arrows), followed by a negative T-wave (arrowheads).

ARVC (Figure 3B) and Brugada syndrome (Figure 1).^{61,62,64,65} Rarely, athletes may require pharmacological testing with sodium channel blocking agents, electrophysiological study, or cardiac imaging to exclude or confirm underlying pathology and risk.

In athletes presenting with syncope or cardiac arrest, which remain unexplained after a detailed clinical work-up aimed to exclude cardiac causes and neuromediated mechanisms, the ECG pattern of early repolarization in inferior and/or lateral leads, particularly when associated with a prominent terminal QRS slurring, should raise the suspect of an underlying idiopathic ventricular fibrillation.⁶³

Uncommon and training-unrelated electrocardiogram changes

Most cardiovascular conditions responsible for SCD in young competitive athletes are clinically silent and unlikely to be suspected or diagnosed on the basis of spontaneous symptoms.^{11–13} The

25-year Italian screening experience has demonstrated that 12-lead ECG has a substantial incremental value over and above history and physical examination for identifying asymptomatic athletes who have potentially lethal heart disorders.^{17–23,66–69} Electrocardiogram-detectable cardiovascular diseases include cardiomyopathies, such as HCM, ARVC, and dilated cardiomyopathy; aortic valve stenosis; cardiac ion-channel diseases such as long-QT syndrome (LQTS), Brugada syndrome, short-QT syndrome (SQTS), and Lenègre disease; and Wolff–Parkinson–White (WPW) syndrome. On the basis of published series from the USA and Italy, these conditions account for approximately two-thirds of SCD in young competitive athletes.^{26,27} Electrocardiogram abnormalities associated with these cardiovascular diseases include repolarization abnormalities such as inverted T-waves and ST-segment depression, pathological Q-waves, conduction disease including left-axis deviation, ventricular pre-excitation, long- and short-QT interval, and Brugada-like repolarization changes (Table 1).

Unlike the ECG changes characteristic of athlete's heart, such ECG abnormalities are relatively uncommon (<5%) and

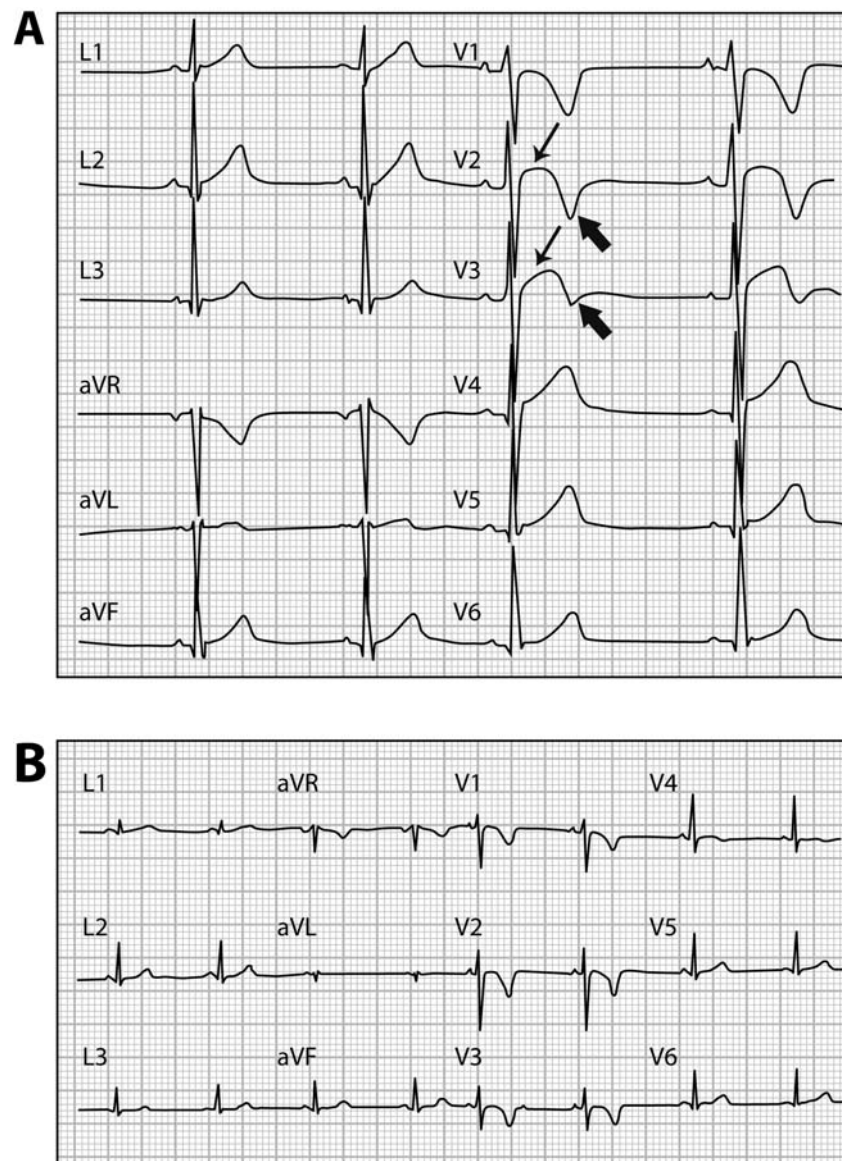


Figure 3 (A) Early repolarization pattern in a healthy black athlete characterized by right precordial T-wave inversion (arrowhead) preceded by ST-segment elevation (arrow). (B) Right precordial T-wave inversion in a patient with ARVC. Note that unlike early repolarization, in the ARVC the right precordial leads do not demonstrate any elevation of the ST-segment.

training-unrelated. Further diagnostic work-up is mandatory for those athletes who exhibit such ECG changes in order to confirm (or exclude) an underlying cardiovascular disease.

Non-voltage criteria for left ventricular hypertrophy

Electrocardiogram offers the potential to distinguish between pathological and physiological hypertrophy, given that ECG abnormalities of structural heart diseases manifesting with LV hypertrophy, such as cardiomyopathies, valve diseases, or hypertensive heart disease overlap only marginally with training-related ECG changes. HCM is the leading cause of SCD in apparently healthy competitive athletes age less than 35 years. This condition

is often in the differential diagnosis with adaptive changes of athlete's heart. An isolated QRS voltage criterion for LV hypertrophy (Sokolow–Lyon or Cornell criteria) is a very unusual pattern (1.9%) in HCM patients in whom pathological LV hypertrophy is characteristically associated with one or more additional non-voltage criteria such as left atrial enlargement, left-axis deviation, delayed intrinsicoid deflection, ST-segment and T-wave abnormalities, and pathological Q-waves (Figure 4).^{70–72}

Recommendation

Regardless of family and personal history, athletes with non-voltage criteria for LV hypertrophy require an echocardiographic evaluation in order to exclude underlying structural heart disease and pathological LV hypertrophy.

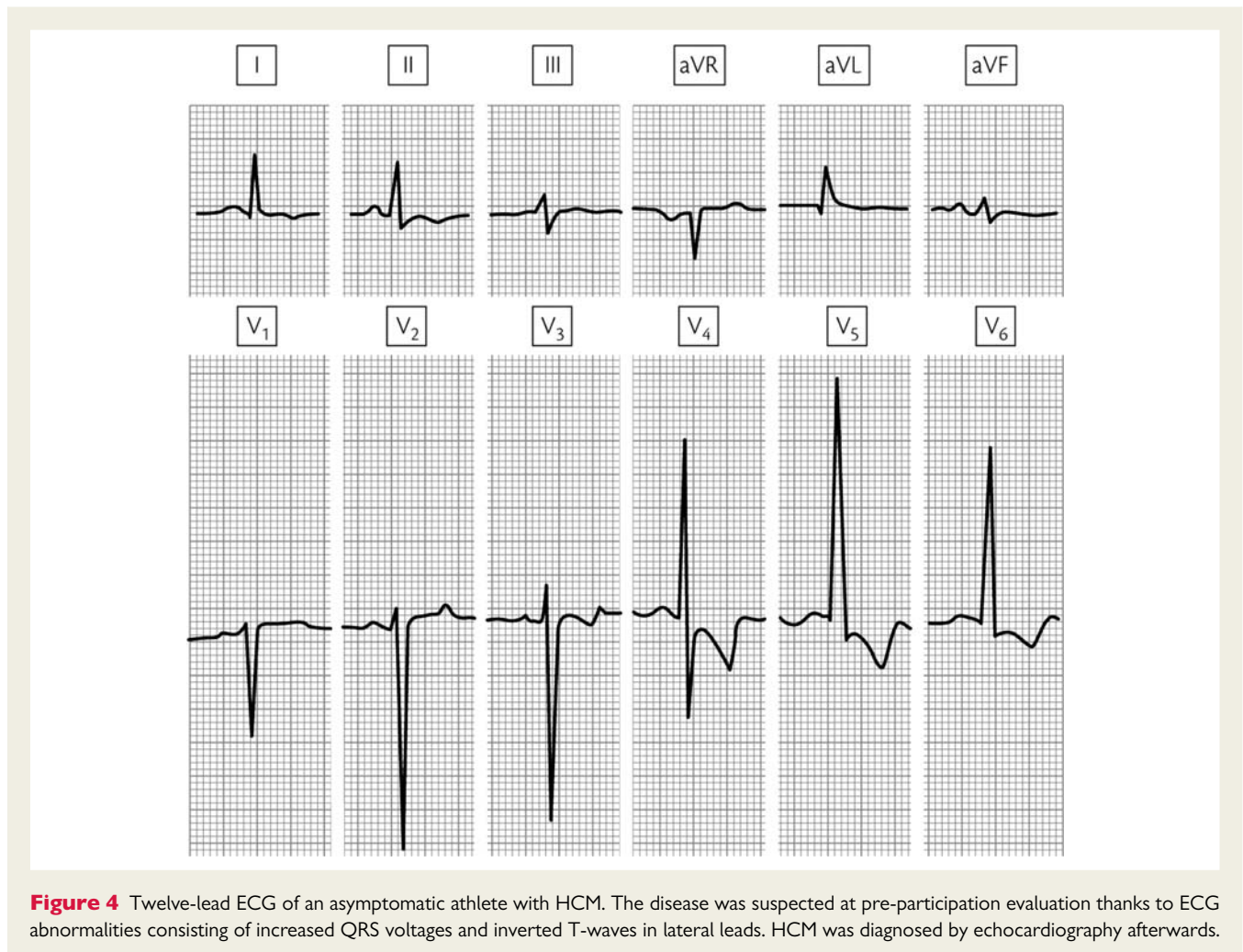


Figure 4 Twelve-lead ECG of an asymptomatic athlete with HCM. The disease was suspected at pre-participation evaluation thanks to ECG abnormalities consisting of increased QRS voltages and inverted T-waves in lateral leads. HCM was diagnosed by echocardiography afterwards.

ST-segment depression

Although ST-segment elevation due to early repolarization is a common finding in the basal ECG of trained athletes, resting ST-segment depression is rarely observed.^{14–16} In the literature, ST-segment depression is usually lumped together with T-wave inversion, making the real incidence of isolated ST-segment depression unknown.¹⁴

Recommendation

Demonstration of ST-segment depression on resting ECG, either isolated or associated with T-wave inversion, should prompt further investigations to exclude heart disease.

Right atrial enlargement and right ventricular hypertrophy

Electrocardiogram evidence of right atrial enlargement and/or RV hypertrophy are uncommon findings in athletes. Pelliccia et al.²⁴ reported a prevalence of 0.08% for right atrial enlargement and 0.6% for a right-axis deviation ($>110^\circ$) among a large cohort of highly conditioned athletes. Sokolow–Lyon voltage criteria for RV hypertrophy ($R-VI+S-V5 > 10.5$ mm) were seen in one of 172 (0.6%) professional soccer players.⁷³ A higher prevalence of

the Sokolow voltage criterion for RV hypertrophy was reported by Sharma et al.³³ among junior elite athletes (12%), although there was no difference with controls (10%). Indeed, a significant proportion of athletes and non-athletes in this study were younger than 16 years, and in such age-group a voltage criterion for RV hypertrophy is more common.

Recommendation

Though uncommon, if present the ECG pattern of atrial enlargement and/or RV hypertrophy should not be interpreted as a manifestation of exercise-induced cardiac remodelling. The presence of either congenital or acquired heart diseases associated with an increased right atrial size and/or pathological RV dilatation/hypertrophy should be excluded.

T-wave inversion

Recent studies on large athletic populations disproved the traditional idea that T-wave inversions are common and training-related ECG changes in the athlete. Pelliccia et al.²⁴ reported a 2.7% prevalence of T-wave inversion in 1005 highly trained athletes and 2.3% in a large population of 32 652 young amateur athletes. Moreover, Sharma et al.³³ reported that the prevalence of T-wave inversion is similar among elite athletes

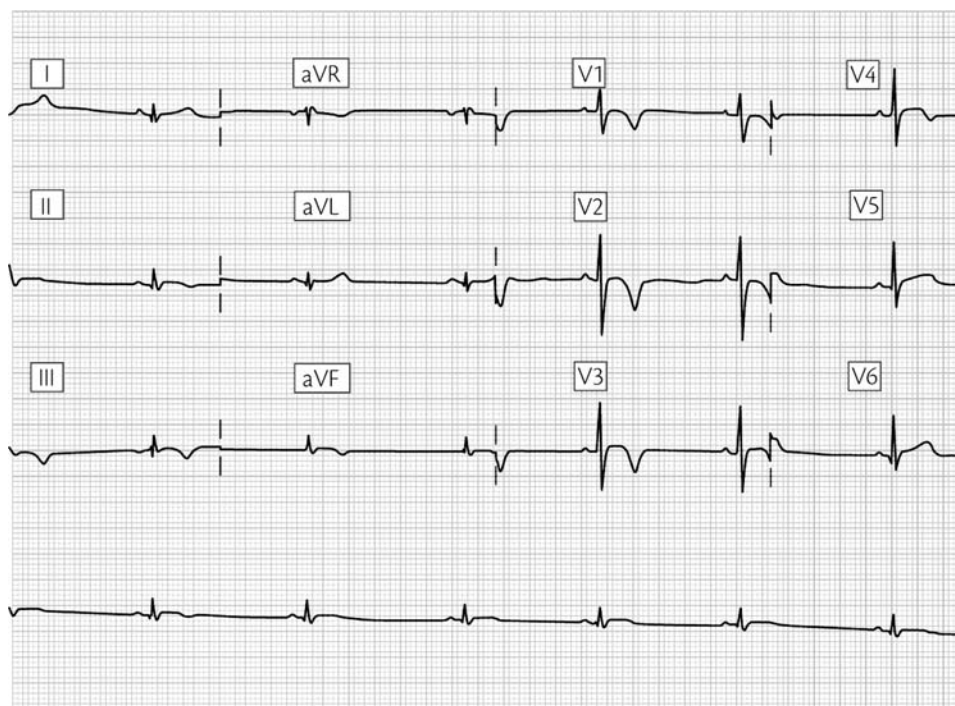


Figure 5 Twelve-lead ECG in an asymptomatic athlete with ARVC. The athlete was referred for further echocardiographic examination and cardiac magnetic resonance because of ECG abnormalities found at pre-participation evaluation which consisted of inverted T-waves in the inferior and anteroseptal leads and low QRS voltages in the peripheral leads.

and sedentary controls (4.4 vs. 4.0%, respectively). The presence of T-wave inversion ≥ 2 mm in two or more adjacent leads in an athlete is a non-specific warning sign of a potential cardiovascular disease at risk of SCD during sports. T-wave inversion in inferior (II, III, aVF) and/or lateral (I, aVL, V5–V6) leads must raise the suspicion of ischaemic heart disease, cardiomyopathy, aortic valve disease, systemic hypertension, and LV non-compaction.^{24,67,74} The post-pubertal persistence of T-wave inversion beyond V1 may reflect an underlying congenital heart disease leading to a RV volume or pressure overload state, ARVC, and uncommonly, an inherited ion-channel disease. Recent studies showed that T-wave inversion beyond V1 is seen in post-pubertal athletes less commonly than previously thought ($<1.5\%$), but deserves special consideration because it may reflect underlying ARVC (Figure 5).^{75,76}

T-wave inversion in young and apparently healthy athletes may represent the initial phenotypic expression of an underlying cardiomyopathy, prior to the development of morphological changes detectable on cardiac imaging.⁷⁷ Thus, failure to detect structural abnormalities on imaging does not exclude underlying heart muscle disease, as this may only become evident over time, but may nonetheless be associated with risk of sudden cardiac death.^{74,77}

Recommendation

T-wave inversion ≥ 2 mm in two or more adjacent leads is rarely observed on the ECG of healthy athletes, whereas it is a common finding in patients with cardiomyopathy and other cardiac disease.

Inverted T-waves may represent the only sign of an inherited heart muscle disease even in the absence of any other features or before structural changes in the heart can be detected. Hence, the perspective that T-wave inversion is due to cardiovascular adaptation to physical exercise should only be accepted once inherited forms of cardiovascular disease have been definitively excluded by a comprehensive clinical work-up, including family evaluation, and mutation analysis when available/appropriate. In this regard, athletes with post-pubertal persistence of T-wave inversion beyond V1 require further clinical and echocardiographic evaluation to exclude an underlying cardiomyopathy such as ARVC or HCM. The recent observation that T-wave inversion may identify athletes at risk for subsequent development of structural heart disease, underscores the importance of continued clinical surveillance and follow-up by serial ECG and echocardiography evaluations of trained athletes with T-wave repolarization abnormalities, even in the absence of clinically demonstrable heart disease.⁷⁴

In healthy athletes of African/Caribbean origin, inverted T-waves, usually preceded by ST-segment elevation, are commonly observed in leads V2–V4 (up to 25% of cases) (Figure 3A) and represent adaptive early repolarization changes which normalize during exercise or adrenergic stimulation.³⁵ On the contrary, T-wave inversion in inferior (L2, L3, aVF) and/or lateral leads (L1, aVL, V5, and V6) are uncommon even in black athletes and warrant further investigation for excluding an underlying heart disease.

The significance of minor T-wave changes such as flat and/or minimally inverted (<2 mm) T-waves in two or more leads (mostly inferior and/or lateral) is unclear. These changes usually

revert to normal with exercise and in this setting may be a benign phenomenon resulting from increased vagal tone. Like deep inverted T-waves, minor T-wave abnormalities are infrequently encountered in the athlete heart (<0.5%),³³ but are common in cardiomyopathy. This indicates that they may have a pathological basis and should be investigated and followed-up over time before they are definitively ascribed to physiological neuro-autonomic remodelling.

Intraventricular conduction abnormalities

Complete bundle branch block (QRS duration ≥ 120 ms), and hemiblocks are uncommon in athletes (<2% of athlete's ECGs) and represent a potential marker of serious underlying cardiovascular disease.^{78–81} The prevalence of complete RBBB and LBBB is low in the general population, particularly in the younger age groups, occurring in $\sim 0.6\%$ of males and 0.3% of females, age less than 40 years. A comparable incidence of either complete LBBB or RBBB has been reported by Pelliccia et al.²⁴ in large athletic population of highly trained competitors (0.4%) and amateur athletes ($\leq 1\%$).

Bundle branch block may develop as a consequence of a primary degenerative lesion of the specialized conducting tissue or from a variety of cardiac pathologies, e.g. ischaemic and hypertensive heart disease, cardiomyopathies, myocarditis, channelopathies, cardiac tumours, sarcoidosis, Chagas' disease, and unoperated and operated congenital heart disease.^{78–81} Complete RBBB is uncommon in healthy individuals/athletes and may represent an idiopathic, isolated and clinically benign conduction interruption/delay through the right bundle branch, whereas LBBB is very rare in otherwise healthy individuals.^{82,83} This latter conduction disturbance is a strong ECG marker of an underlying structural cardiovascular disorder and may occur as an early and isolated manifestation of ischaemic heart disease or cardiomyopathy, many years before structural changes in the LV can be detected. Intermittent, rate-dependent LBBB may occur as a precursor and, thus, have the same clinical and prognostic significance of stable LBBB.

Left anterior hemiblock is more common in men and increases in frequency with advancing age. The estimated prevalence in the general population (age less than 40 years) is 0.5–1.0%, a figure similar to that reported in the athletic population.^{24,81} Although isolated left anterior hemiblock is usually an incidental ECG finding in subjects without evidence of structural heart disease, the association with a variety of cardiovascular disorders has been reported. Isolated left posterior hemiblock is a very rare finding, being usually associated with RBBB. Combinations of bundle branch block and hemiblock reflect a more extensive involvement of the specialized conduction system and carry an increased risk of clinically significant AV block.⁸¹

Recommendation

Demonstration of complete bundle branch block and/or hemiblock in an athlete should lead to a cardiological work-up including exercise testing, 24 h ECG, and imaging for the evaluation of underlying pathological causes.

An ECG should be obtained in the siblings of a young athlete with an ECG pattern of bifascicular block (i.e. LBBB, RBBB and

left anterior hemiblock, or RBBB and left posterior hemiblock) to exclude a genetically determined progressive cardiac conduction disease (Lènegre disease).⁸⁴ Lènegre disease is an autosomal dominant condition that has been linked to mutations of the *SCN5A* gene which encodes for cardiac sodium ion channels. Clinical phenotype consists of various combinations of conduction defects or AV block which characteristically occur in young individuals.

Non-specific intraventricular conduction defects

A prolonged QRS (>110 ms) not satisfying the criteria for either LBBB or RBBB is referred to as non-specific intraventricular conduction disturbance.⁸⁵ Because the conduction delay occurs in the ventricular myocardium rather than in the specialized conduction system, this conduction defect is a particular indicator of a possible heart muscle disease and requires further cardiovascular investigation. For instance, localized prolongation of the QRS complex (>110 ms) in the right precordial leads (V1–V3), often associated with an 'epsilon wave' (i.e. a terminal notch in the QRS complex) and/or delayed S-wave upstroke, is an ECG marker for ARVC (Figure 6).

Ventricular pre-excitation (Wolff–Parkinson–White)

The prevalence of ventricular pre-excitation in the general population varies from 0.1 to 0.3% and is similar in athletes.⁸⁶ Most individuals with WPW pre-excitation syndrome remain asymptomatic throughout their lives. When symptoms do occur, they are usually secondary to reciprocating supraventricular tachycardia which causes disabling symptoms. The WPW patients, however, may also develop other arrhythmias such as atrial fibrillation, which could degenerate into ventricular fibrillation and SCD, as a result of rapid conduction over an AV accessory pathway with a short-antegrade refractory period.⁸⁷ The risk of SCD associated with ventricular pre-excitation is $\sim 0.15\%$ per year in asymptomatic individuals and 0.25% per year in symptomatic patients.^{88–90} It has been estimated that one-third of patients with WPW syndrome may develop atrial fibrillation. Exercise has been reported to be associated with an increased risk of developing ventricular fibrillation.⁸⁴ Moreover, athletes may have an increased risk of AF even after they have ceased high-level sports competition. Therefore, sports activity may expose an athlete with ventricular pre-excitation to increased risk of SCD.^{13,30}

Recent studies have indicated that WPW syndrome rarely is genetically determined. Pathogenetic mutations are located in the gene encoding for the regulatory $\gamma 2$ -subunit (*PRKAG2*) of the AMP-activated protein kinase.⁹¹ Familial WPW syndrome is inherited as an autosomal dominant tract with variable clinical expressivity. The clinical phenotype is characterized by the association between ventricular pre-excitation and progressive ventricular hypertrophy. Supraventricular tachyarrhythmias, progressive AV conduction disease and heart failure are common and there are reports of associated skeletal muscle involvement.⁹² Clinical features, biochemical studies, and experimental animal model

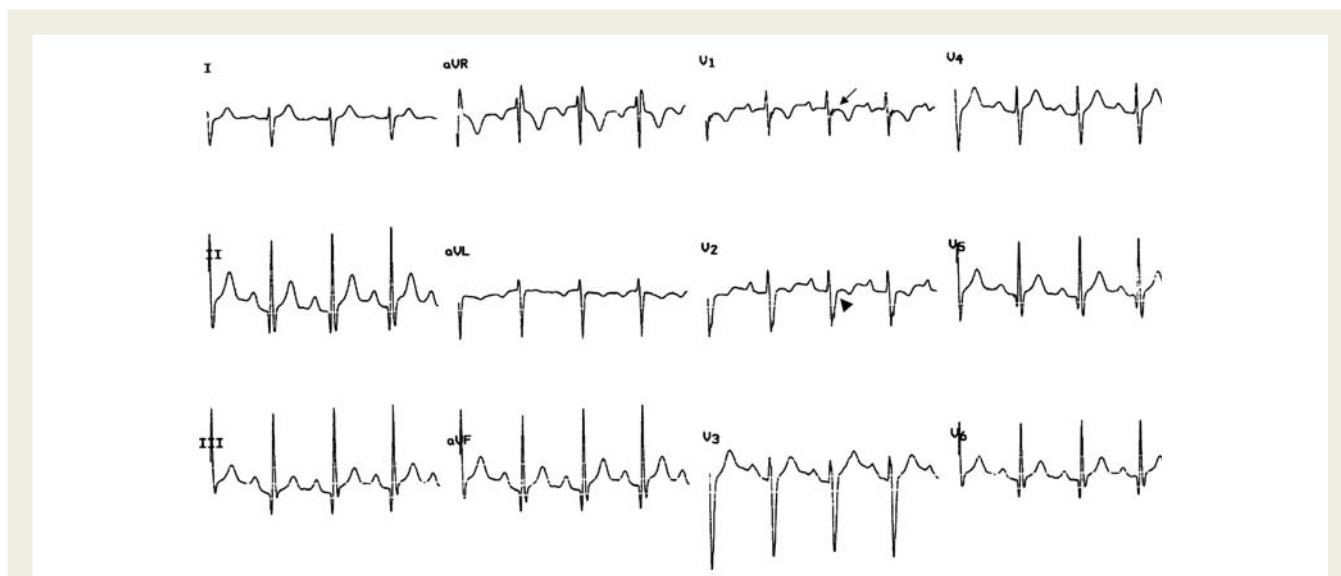


Figure 6 ECG recording of a patient with ARVC showing non-specific RV conduction defect, which is characterized by an increase of QRS duration (115 ms) in the right precordial leads, associated with an epsilon wave (arrow) in V1 (i.e. a low amplitude, low-frequency wave occurring after the end of the QRS) and a prolonged S-wave upstroke in V1 and V2 (arrowhead).

support the notion that the *PRKAG2*-related familial WPW syndrome is a novel cardiac-specific glycogenesis syndrome.

Recommendation

The history should address the presence of symptoms (palpitation or syncope) and family background of pre-excitation, cardiomyopathy, or sudden death. Twenty-four hours ECG, exercise testing, and pharmacological testing with adenosine/verapamil may help in reaching definitive diagnosis and assessing the arrhythmic risk. Intermittent loss or sudden disappearance during exercise of the WPW pattern suggests a long anterograde refractory period of the accessory pathway to account for slow ventricular response during atrial fibrillation and thus low risk of sudden death. If latent pre-excitation is suspected, the typical WPW ECG features can be unmasked by simple bedside interventions, such as vagal manoeuvres and intravenous adenosine or verapamil, aimed to either slow or block the conduction over the AV-node.

Less common variants of ventricular pre-excitation with nodoventricular or fasciculo-ventricular Mahaim fibres should be identified because of their different clinical manifestations and prognosis. Although a short-PR interval (≤ 0.12 s) without delta wave has been reported as a normal variant of athlete's ECG,²⁴ it needs a careful evaluation because may reflect either a ventricular pre-excitation syndrome (Lown–Genong–Levine syndrome) or an underlying structural heart disease (such as HCM or Fabry's disease).

Athletes with a diagnosis of ventricular pre-excitation should be referred to a specialist for evaluation by electrophysiological study (either transesophageal or intracardiac) for the inducibility of AV re-entrant tachycardia and refractoriness of the accessory pathway (shortest pre-excited RR interval at rest and during exercise or adrenergic drug stimulation), which may influence eligibility to athletic competition, risk stratification, and therapy, including

catheter ablation. Further investigations should include echocardiography to rule out an associated structural heart disease, such as Ebstein anomaly, HCM, or glycogen storage cardiomyopathy.

Long-QT interval

The duration of the QT interval (i.e. the interval between the beginning of the QRS complex and the end of the T-wave) changes with heart rate and it is usually corrected (QTc) by using Bazett's formula $QTc = QT/\sqrt{RR}$.^{93,94} The QT interval should be measured in L2, V3, or V5; the longest value (return to baseline) should be considered. The calculation of the QT interval in athletes has inherent limitations due to sinus arrhythmia, slightly widened QRS complexes and T–U complexes. Corrections for heart rates may be inaccurate at heart rates ≤ 40 and > 120 b.p.m.

QT interval is modulated by gender and therefore different cut-off values are used after puberty. A QTc interval is traditionally considered long in men when it is more than 440 ms and in women when it exceeds 460 ms, but some have suggested values up to and above 470 ms in male and 480 ms in female.^{95–97} In general, QT interval is longer in athletes than in non-athletic controls because of the lower resting heart rate associated with athletic training, while the QTc of the athletic group is within normal limits, though toward the upper limit.^{14,93,94}

Recording of QTc intervals beyond the normal cut-off values should raise the suspicion of either acquired or congenital long-QT syndrome (LQTS).^{93,94,98,99} The most frequent cause is the use of QT-prolonging drugs, which block the delayed rectifier IKr current. Other causes of acquired LQTS are bradycardia, metabolic changes, and electrolyte disorders, abnormalities which are associated with intense athletic activity. Long-QT syndrome is a genetically determined ion-channel disease that may cause life-threatening ventricular arrhythmias such as torsades-de-pointes

and ventricular fibrillation.⁹⁹ The LQTS genes encode ion-channel subunits involved in the repolarization phase of the cardiac action potential. Approximately 90% of genotype positive patients have a mutation in three genes: *KCNQ1* (LQT1), *KCNH2* (LQT2), or *SCN5A*. Loss-of-function mutations of *KCNQ1* (LQT1) and *KCNH2* (LQT2) genes are associated with impaired function of cardiac potassium channels regulating outward K⁺ currents active during late ventricular repolarization. Gain-of-function mutations of *SCN5A* gene, instead, account for the rare and highly malignant LQT3 variant which is characterized by impaired function of cardiac Na⁺ channels with late persistent inward currents delaying ventricular repolarization. Different molecular mechanisms may explain differences seen in clinical manifestations and circumstances of arrhythmic events in patients with different genotypes. LQT1 patients are prone to syncope or cardiac arrest during physical exercise, mostly while swimming. LQT2 subjects are more susceptible during emotional stress and acoustic stimuli. LQT3 patients show a bradycardia-dependent QT prolongation and they usually experience SCD at rest (while sleeping). Molecular screening for gene mutations in patients with LQTS has important prognostic implications, because genotype is an independent predictor of clinical outcome.

Although prolongation of the QT interval on basal 12-lead ECG is the most significant expression of LQTS, the accompanying ST-segment and T-wave changes may be of additional diagnostic value. T-wave abnormalities may correlate with specific genotypes: normal or broad-based T-waves are more often seen in LQT1, bifid T-waves in LQT2, and late-onset peaked/biphasic T-waves in LQT3.¹⁰⁰

Recommendation

When an abnormally prolonged QTc interval is identified, potential transient causes of acquired QT prolongation should be carefully evaluated. Delayed repolarization secondary to a structural heart disease should be excluded by an echocardiogram.

It has been suggested that the demonstration of a QTc value of ≥ 500 ms, otherwise unexplained, is indicative of unequivocal LQTS, regardless of family history and symptoms.

Athletes with QTc intervals >440 ms (males)/ 460 (females) and <500 ms represent a 'grey zone' which requires detailed assessment to achieve a definitive diagnosis. A careful family and personal history is important for the assessment of the genetic nature and the presence of relevant symptoms, such as syncopal episodes, which increase the probability of LQTS.⁹⁸ The accurate assessment of family history of LQTS should include cascade ECG screening and QTc interval measurement of family members. Twenty-four hours ECG permits serial evaluation which may reveal QTc prolongation and associated ST-T morphological abnormalities over time. Exercise testing may enhance diagnostic accuracy because shortening of the QT interval during effort is inadequate and/or repolarization abnormalities may become more prominent and recognizable after exercise in patients with LQTS. The ECG response to exercise may vary according to LQTS genotype: in general, the QTc prolongs in LQT1, remains unchanged in LQT2, and shortens excessively in LQT3 patients; however, exceptions do exist.⁹⁴ Reversal to a normal QTc interval after deconditioning may help in differentiating the adaptive

variations of the QT value, which may occur with intense physical training because of neuro-hormonal and structural changes, from LQTS.⁹³ The athlete with suspected LQTS should be referred to a specialist for diagnostic evaluation which may include mutation analysis.

Short-QT interval

There is debate over what constitutes a short-QT interval and the lower limit of normal changes with age. Values of 330 ms (310 ms in children) for the QT and between 360 and 380 ms for the QTc have been proposed: QT or QTc intervals below these values can therefore be considered abnormally short.¹⁰¹ For the correct determination of the QT interval, the heart rate should preferably be less than 80 b.p.m.

Short-QT syndrome is an inheritable ion-channel disease that is characterized by an abnormally short cardiac repolarization predisposing to life-threatening ventricular arrhythmias.^{101,102} QT interval in symptomatic index patients has been reported to be consistently ≤ 320 ms (QTc ≤ 340 ms). In addition to the abnormally short-QT interval, individuals with SQTS have associated ventricular repolarization abnormalities including a short or even absent ST-segment and morphologically abnormal T-waves that are tall, narrow, and symmetrical in the precordial leads. Short-QT syndrome has been linked to defective genes encoding potassium channels (*KCNH2*, *KCNQ1*, *KCNJ2*) or L-type calcium channel (*CACNA1C* and *CACNB2b*).^{101–103} Shortening of repolarization accounts for short myocardial refractoriness which predisposes to atrial or ventricular fibrillation in the absence of structural heart disease.

Recommendation

After identification of an abnormally short-QTc interval in an athlete (QTc <380 ms), causes of transient QT shortening, such as hypercalcaemia, hyperkalemia, hyperthermia, acidosis, and some drugs (e.g. digitalis), must be ruled out. It has been recently reported that a QTc interval ≤ 380 ms in strength trained athletes may be a marker of abuse of anabolic androgenic steroids.¹⁰⁴ In the absence of acquired causes of short-QT interval, the athlete should be referred for familial ECG-clinical screening and molecular genetic evaluation.

Brugada-like electrocardiogram abnormalities

The distinctive Brugada ECG consists of an early, high take-off (≥ 2 mm), and downsloping ST-segment elevation ('J-wave') of either the 'coved' (negative T-wave) or 'saddle-back' (positive T-wave) type in V1–V2/V3 (Figures 1 and 7). The Brugada syndrome is characterized by the typical ECG abnormalities and the increased vulnerability to ventricular fibrillation and SCD, in the absence of clinical evidence of structural heart disease.^{105,106} In about one-fourth of cases, the syndrome has been linked to a genetic dysfunction of cardiac sodium channels due to a mutation in the *SCN5A* gene. Three different types of repolarization abnormalities have been described, of which only the most prominent form (Type 1) is diagnostic¹⁰⁵ (Figure 7). Provocation by class-1 anti-arrhythmic drugs (flecainide or ajmaline) may be used to unmask the diagnostic Type 1 ('coved' type) Brugada ECG in

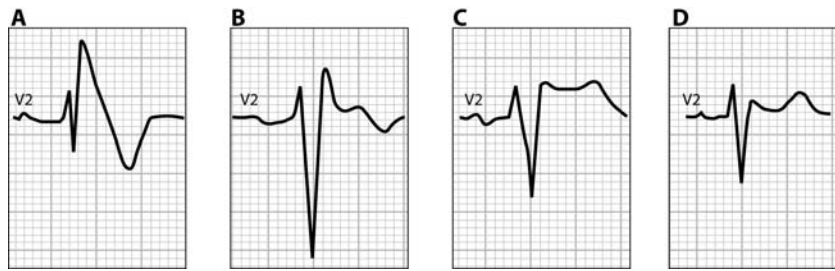


Figure 7 Patterns of Brugada ECG. Type 1 Brugada ECG is characterized by a ‘coved’ ST-segment elevation ≥ 2 mm (0.2 mV) followed by a negative T wave (A). The Type 2 Brugada ECG shows a ‘saddleback’ morphology with a high takeoff (≥ 2 mm) ST-segment elevation, remaining ≥ 1 mm above the baseline, followed by a biphasic (B) or positive (C) T-wave. Type 3 has either a coved or saddleback morphology with J point elevation ≥ 2 mm but the terminal portion of ST-segment < 1 mm (D).

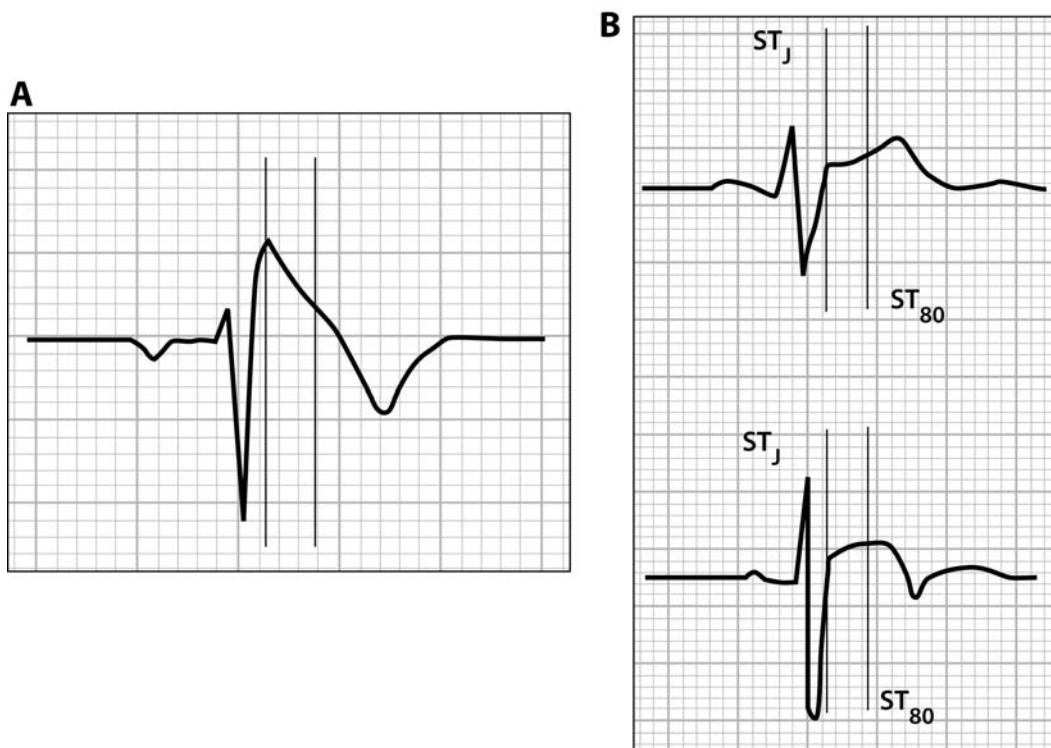


Figure 8 Differential diagnosis between representative right precordial ECG patterns from (A) a Brugada patient and (B) two trained athletes. Vertical lines mark the J-point (ST_j) and the point 80 ms after the J-point (ST_{80}) where the amplitudes of ST-segment elevation are calculated. ‘Coved’ type ST-segment elevation in the patient with Brugada syndrome is characterized by a ‘downsloping’ elevated ST-segment with a ST_j/ST_{80} ratio of 1.9. Right precordial early repolarization patterns in both athletes show an ‘upsloping’ ST-segment elevation with ST_j/ST_{80} ratio < 1 ; 0.7 for the ‘concave’ toward the top (B, top) and 0.68 for the ‘convex’ toward the top (B, bottom) ST-segment elevation. Modified from Corrado *et al.*⁶²

individuals with Type 2 and 3 patterns (‘saddle-back’ type) (Figure 1). An S1, S2, S3 pattern, which may mimic a left anterior hemiblock, is frequently associated with the Brugada repolarization abnormalities and most likely reflects a concomitant intraventricular conduction defect localized to the right ventricular outflow tract due to the disease involvement of the peripheral fascicles of the right bundle branch distributing to the RV infundibum.¹⁰⁷

Dynamic ECG changes over time are common and may lead to a transient, complete normalization of the ECG. A febrile state, electrolyte disturbances or manoeuvres/circumstances associated with an increased vagal tone have been reported to enhance the ST-segment elevation/J-wave and trigger rapid polymorphic ventricular tachycardia and/or cardiac arrest with ventricular fibrillation.¹⁰⁸ Although in Brugada syndrome SCD is typically unrelated

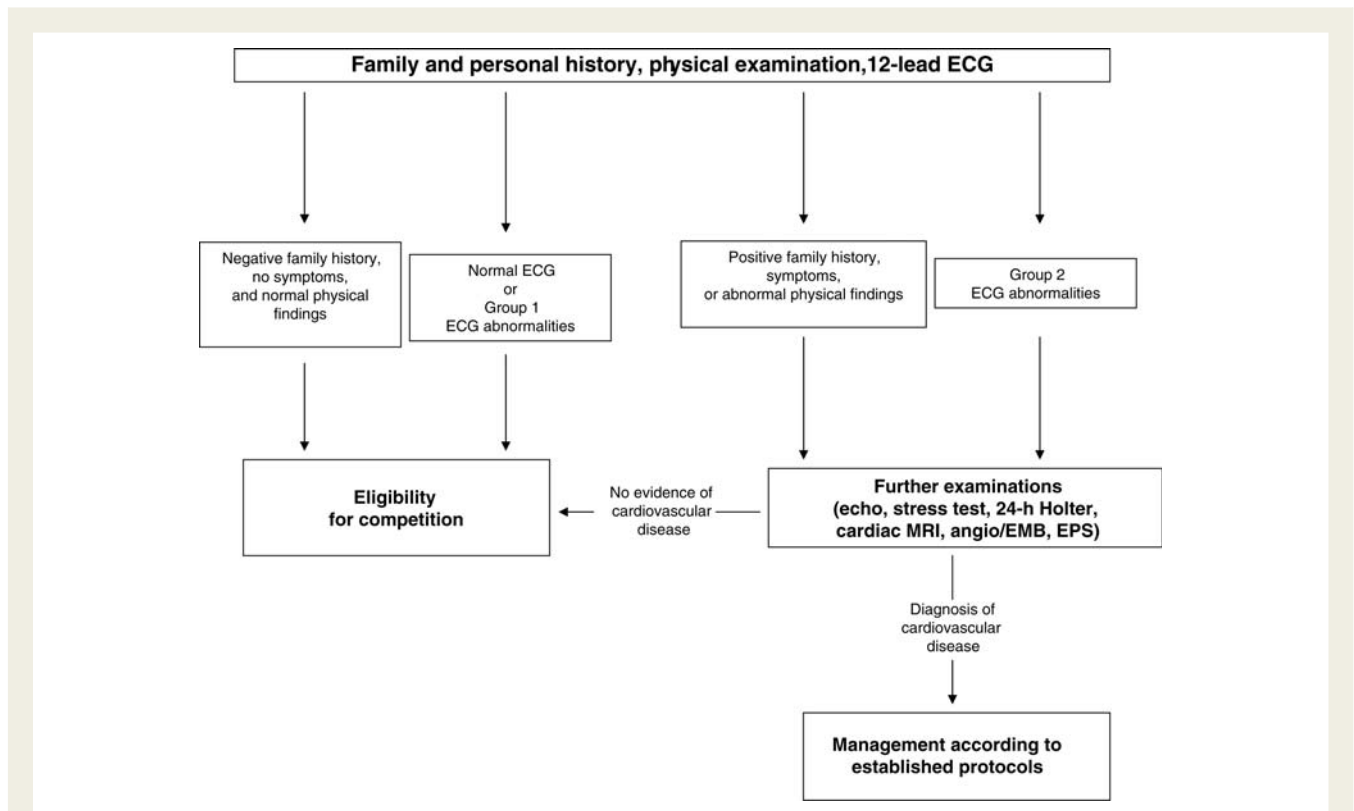


Figure 9 Flow diagram illustrating screening work-up according to the proposed criteria for ECG interpretation in trained athletes. The initial cardiovascular protocol includes family and personal history, physical examination (with determination of blood pressure), and basal 12-lead ECG. Additional tests are requested only for athletes who have a positive family history of cardiac disease/premature sudden death, relevant symptoms, abnormal physical findings, or Group 2 ECG abnormalities. In athletes with a negative familial/personal history and a normal physical examination, the finding of ECG changes due to cardiac adaptation to physical exertion (Group 1) should allow participation in competitive sport activity without additional investigations. Athletes diagnosed with clinically relevant cardiovascular abnormalities are managed according to available guidelines for assessing athletic risk. In athletes with Group 2 ECG abnormalities, in the absence of other evidence of cardiovascular disease, it is important to exclude incomplete disease expression of inherited cardiac conditions, such as HCM, ARVC, or ion-channel diseases. Group 1 and Group 2 ECG abnormalities are reported in Table 1. EMB, endomyocardial biopsy; EPS, electrophysiologic study; MRI, magnetic resonance imaging.

to physical exercise, the increased vagal tone which develops as a consequence of the sustained athletic conditioning may enhance the propensity to die suddenly at rest, mostly just after exercise performance as a result of the increased vagal tone rebound. In addition, hyperthermia and/or hypokalemia which often occur during strenuous exercise might act as potential triggers of life-threatening ventricular arrhythmias in affected athletes.⁵³

Recommendation

Analysis of the ST-T waveform usually permits differential diagnosis between a Brugada ECG and right precordial early repolarization seen in athlete's heart. Athletes exhibit an *upsloping* ST-segment with a mean ST_T/ST_{80} ratio ≤ 1 , whereas Brugada patients show a *downsloping* ST-segment with a ST_T/ST_{80} ratio > 1 (Figure 8).⁶² The athlete with a suspected Brugada ECG should be referred to a cardiologist/electrophysiologist for further clinical work-up, including a pharmacological test with sodium channel blocking (Figure 1), risk stratification, and familial evaluation.

Implications for pre-participation screening

Previous consensus has been that ECG may be abnormal in up to 50% of athletes, which is the main criticism for the widespread use of ECG as part of pre-participation screening. Defining what ECG changes are physiological (common and training-related ECG abnormalities) and what are pathological (uncommon and training-unrelated ECG abnormalities) is expected to lower the traditional high number of false-positives, thus reducing unnecessary investigations. To approximate the impact of the new approach to ECG interpretation in the athlete, the proposed criteria were applied to the 1005 ECGs of highly trained athletes previously reported by Pelliccia et al.²⁴ In the original study, the ECGs were classified into three subgroups, as distinctly abnormal, mildly abnormal, and normal (or with minor alterations). Abnormal ECG was identified in 402 athletes (40%): distinctly abnormal in 145, and mildly abnormal in 257. In the remaining 603 athletes (60%), ECGs were normal or exhibited only minor alterations,

which were deemed typical of the athlete's heart. Of the 402 athletes with ECG abnormalities previously classified as abnormal and suggestive of cardiac disease, 292 (70%) exhibited either an isolated increase of QRS voltages (233 athletes) or an early repolarization pattern (59 athletes), which were re-classified according to the new criteria as 'physiological' (common and training-related) ECG changes. The other 110 (11%) athlete's ECGs previously classified as abnormal because of repolarization abnormalities, intraventricular conduction defects, pathological Q-waves, and WPW pattern, remained 'pathological' (uncommon and training-unrelated) based on the new criteria. Thus, the effect of the use of the proposed criteria is to substantially increase the ECG specificity (by $\approx 70\%$), primarily in the important group of athletes who exhibit pure voltage criteria for LV hypertrophy and early repolarization abnormalities, but with the important requisite of maintaining sensitivity for detection (or suspicion) of cardiovascular diseases at risk of SCD during sports.

Conclusions

The present position paper provides a modern approach to correct interpretation of the athlete's ECG. The main objective was to offer clues for distinction between physiological, training-related ECG patterns, and potentially pathological, training-unrelated ECG abnormalities. This approach has important implications for the cardiovascular management of the athlete, including pre-participation screening, clinical diagnosis, and risk stratification. According to the proposed criteria/recommendation, further diagnostic evaluation is limited to the small subset of athletes with uncommon and not sports-related ECG changes, which may reflect a potentially lethal heart disease. On the contrary, ECG changes due to cardiac adaptation to physical exertion, commonly observed in the trained athletes, should provide reassurance to continue to participate in competitive sports without additional investigations, in the absence of symptoms or a family history of cardiac disease/premature SCD (Figure 9). The use of these updated ECG criteria is expected to improve ECG accuracy in the evaluation of trained athletes, with a lower proportion of total positive and false-positive rates results, and lead to a considerable cost savings in the context of a pre-participation screening process.

The future for prevention of SCD in the athlete by large-scale ECG screening program lies in continuing efforts to better understand the scientific basis for ECG interpretation and to define standards of ECG criteria for differentiation between athlete's heart and true heart diseases. Further studies are needed to test the accuracy, utility, and cost-effectiveness of the present ECG criteria in relation to gender, age, ethnicity, and different level of training and/or type of sports.

Funding

This work was supported by the Ministry of Health, Rome; and Fondazione Cariparo, Padova and Rovigo; Italy.

Conflict of interest: none declared.

References

- Fletcher GF, Balady G, Blair SN, Blumenthal J, Caspersen C, Chaitman B, Epstein S, Sivarajan Froelicher ES, Froelicher VF, Pina IL, Pollock ML. Statement on exercise: benefits and recommendations for physical activity programs for all Americans. A statement for health professionals by the Committee on Exercise and Cardiac Rehabilitation of the Council on Clinical Cardiology, American Heart Association. *Circulation* 1996;**94**:857–862.
- Thompson PD, Buchner D, Pina IL, Balady GJ, Williams MA, Marcus BH, Berra K, Blair SN, Costa F, Franklin B, Fletcher GF, Gordon NF, Pate RR, Rodriguez BL, Yancey AK, Wenger NK. Exercise and physical activity in the prevention and treatment of atherosclerotic cardiovascular disease: a statement from the Council on Clinical Cardiology (Subcommittee on Exercise, Rehabilitation, and Prevention) and the Council on Nutrition, Physical Activity, and Metabolism (Subcommittee on Physical Activity). *Circulation* 2003;**107**:3109–3116.
- Huston P, Puffer JC, MacMillan RW. The athletic heart syndrome. *N Engl J Med* 1985;**315**:24–32.
- Fagard R. Athlete's heart. *Heart* 2003;**89**:1455–1461.
- Oakley CM. The electrocardiogram in the highly trained athlete. *Cardiol Clin* 1992;**10**:295–302.
- Barbier J, Ville N, Kervio K, Walther G, Carré F. Sports-specific features of athlete's heart and their relation to echocardiographic parameters. *Herz* 2006;**31**:531–543.
- Bjørnstad H, Storstein L, Meen HD, Hals O. Electrocardiographic findings in athletic students and sedentary controls. *Cardiology* 1991;**79**:290–305.
- Storstein L, Bjørnstad H, Hals O, Meen HD. Electrocardiographic findings according to sex in athletes and controls. *Cardiology* 1991;**79**:227–236.
- Bjørnstad H, Storstein L, Dyre Meen H, Hals O. Electrocardiographic findings according to level of fitness and sport activity. *Cardiology* 1993;**83**:268–279.
- Bjørnstad H, Storstein L, Meen HD, Hals O. Electrocardiographic findings of repolarization in athletic students and control subjects. *Cardiology* 1994;**84**:51–60.
- Corrado D, Thiene G, Nava A, Rossi L, Pennelli N. Sudden death in young competitive athletes: clinico-pathologic correlations in 22 cases. *Am J Med* 1990;**89**:588–596.
- Maron BJ. Sudden death in young athletes. *N Engl J Med* 2003;**349**:1064–1075.
- Corrado D, Basso C, Thiene G. Sudden death in young athletes. *Lancet* 2005;**366**(Suppl. 1):S47–S48.
- Foote CB, Michaud GF. The Athlete's electrocardiogram: distinguishing normal from abnormal. In: Estes NAM, Salem DN, Wang PJ (eds), *Sudden Cardiac Death in the Athlete*. Armonk, NY: Futura Publishing; 1998. p.101–113.
- Wu J, Stork TL, Perron AD, Brady WJ. The athlete's electrocardiogram. *Am J Emerg Med* 2006;**24**:77–86.
- Holly RG, Shaffrath JD, Amsterdam EA. Electrocardiographic alterations associated with the hearts of athletes. *Sports Med* 1998;**25**:139–148.
- Corrado D, McKenna WJ. Appropriate interpretation of the athlete's electrocardiogram saves lives as well as money. *Eur Heart J* 2007;**28**:1920–1922.
- Corrado D, Basso C, Schiavon M, Pelliccia A, Thiene G. Pre-participation screening of young competitive athletes for prevention of sudden cardiac death. *J Am Coll Cardiol* 2008;**52**:1981–1989.
- Myerburg RJ, Vetter VL. Electrocardiograms should be included in preparticipation screening of athletes. *Circulation* 2007;**116**:2616–2626.
- Papadakis M, Whyte G, Sharma S. Preparticipation screening for cardiovascular abnormalities in young competitive athletes. *Br Med J* 2008;**337**:a1596.
- Drezner JA. Contemporary approaches to the identification of athletes at risk for sudden cardiac death. *Curr Opin Cardiol* 2008;**23**:494–501.
- Corrado D, Basso C, Schiavon M, Thiene G. Screening for hypertrophic cardiomyopathy in young athletes. *N Engl J Med* 1998;**339**:364–369.
- Corrado D, Basso C, Pavei A, Michieli P, Schiavon M, Thiene G. Trends in sudden cardiovascular death in young competitive athletes after implementation of a preparticipation screening program. *J Am Med Assoc* 2006;**296**:1593–1601.
- Pelliccia A, Maron BJ, Culasso F, Di Paolo FM, Spataro A, Biffi A, Caselli G, Piovano P. Clinical significance of abnormal electrocardiographic patterns in trained athletes. *Circulation* 2000;**102**:278–284.
- Pelliccia A, Culasso F, Di Paolo F, Accettura D, Cantore R, Castagna W, Ciacciarelli A, Costini G, Cuffari B, Drago E, Federici V, Gribaudo CG, Iacovelli G, Landolfi L, Menichetti G, Atzeni UO, Parisi A, Pizzi AR, Rosa M, Santelli F, Santillo F, Vagnini A, Casasco M, Di Luigi L. Prevalence of abnormal electrocardiograms in a large, unselected population undergoing preparticipation cardiovascular screening. *Eur Heart J* 2007;**28**:2006–2010.
- Elliott P, McKenna WJ. Hypertrophic cardiomyopathy. *Lancet* 2004;**5**:1881–1891.
- Basso C, Corrado D, Marcus FI, Nava A, Thiene G. Arrhythmogenic right ventricular cardiomyopathy. *Lancet* 2009;**373**:1289–1300.

28. Maron BJ, Zipes DP. 36th Bethesda Conference: recommendations for determining eligibility for competition in athletes with cardiovascular abnormalities. *J Am Coll Cardiol* 2005;**45**:1373–1375.
29. Pelliccia A, Fagard R, Bjornstad HH, Anastassakis A, Arbustini E, Assanelli D, Biffi A, Borjesson M, Carre F, Corrado D, Delise P, Dorwarth U, Hirth A, Heidbuchel H, Hoffmann E, Mellwig KP, Panhuyzen-Goedkoop N, Pisani A, Solberg EE, van-Buuren F, Vanhees L, Blomstrom-Lundqvist C, Deligiannis A, Dugmore D, Glikson M, Hoff PI, Hoffmann A, Hoffmann E, Horstkotte D, Nordrehaug JE, Oudhof J, McKenna WJ, Penco M, Priori S, Reybrouck T, Senden J, Spataro A, Thiene G. Recommendations for competitive sports participation in athletes with cardiovascular disease: a consensus document from the Study Group of Sports Cardiology of the Working Group of Cardiac Rehabilitation and Exercise Physiology and the Working Group of Myocardial and Pericardial Diseases of the European Society of Cardiology. *Eur Heart J* 2005;**26**:1422–1445.
30. Heidbuchel H, Panhuyzen-Goedkoop N, Corrado D, Hoffmann E, Biffi A, Delise P, Blomstrom-Lundqvist C, Vanhees L, Ivarhoff P, Dorwarth U, Pelliccia A Study Group on Sports Cardiology of the European Association for Cardiovascular Prevention Rehabilitation. Recommendations for participation in leisure-time physical activity and competitive sports in patients with arrhythmias and potentially arrhythmogenic conditions. Part I: supraventricular arrhythmias and pacemakers. *Eur J Cardiovasc Prev Rehabil* 2006;**13**:475–484.
31. Heidbuchel H, Corrado D, Biffi A, Hoffmann E, Panhuyzen-Goedkoop N, Hoogsteen J, Delise P, Hoff PI, Pelliccia A Study Group on Sports Cardiology of the European Association for Cardiovascular Prevention Rehabilitation. Recommendations for participation in leisure-time physical activity and competitive sports of patients with arrhythmias and potentially arrhythmogenic conditions. Part II: ventricular arrhythmias, channelopathies and implantable defibrillators. *Eur J Cardiovasc Prev Rehabil* 2006;**13**:676–686.
32. Pelliccia A, Corrado D, Bjornstad HH, Panhuyzen-Goedkoop N, Urhausen A, Carre F, Anastasakis A, Vanhees L, Arbustini E, Priori S. Recommendations for participation in competitive sport and leisure-time physical activity in individuals with cardiomyopathies, myocarditis and pericarditis. *Eur J Cardiovasc Prev Rehabil* 2006;**13**:876–885.
33. Sharma S, Whyte G, Elliott P, Padula M, Kaushal R, Mahon N, McKenna WJ. Electrocardiographic changes in 1000 highly trained junior elite athletes. *Br J Sports Med* 1999;**33**:319–324.
34. Magalski A, Maron BJ, Main ML, McCoy M, Florez A, Reid KJ, Epps HW, Bates J, Browne JE. Relation of race to electrocardiographic patterns in elite American football players. *J Am Coll Cardiol* 2008;**51**:2250–2255.
35. Basavarajiah S, Boraita A, Whyte G, Wilson M, Carby L, Shah A, Sharma S. Ethnic differences in left ventricular remodeling in highly-trained athletes: relevance to differentiating physiologic left ventricular hypertrophy from hypertrophic cardiomyopathy. *J Am Coll Cardiol* 2008;**51**:2256–2262.
36. Montgomery HE, Clarkson P, Dollery CM, Prasad K, Losi MA, Hemingway H, Statters D, Jubb M, Girvain M, Varnava A, World M, Deanfield J, Talmud P, McEwan JR, McKenna WJ, Humphries S. Association of angiotensin-converting enzyme gene I/D polymorphism with change in left ventricular mass in response to physical training. *Circulation* 1997;**96**:741–747.
37. Karjalainen J, Kujala UM, Stolt A, Mäntysaari M, Viitasalo M, Kainulainen K, Kontula K. Angiotensinogen gene M235T polymorphism predicts left ventricular hypertrophy in endurance athletes. *J Am Coll Cardiol* 1999;**34**:494–499.
38. Maron BJ, Pelliccia A. The heart of trained athletes: cardiac remodeling and the risks of sports, including sudden death. *Circulation* 2006;**114**:1633–1644.
39. Hanne-Paparo N, Drory Y, Schoenfeld YS, Kellerman J. Common ECG changes in athletes. *Cardiology* 1976;**61**:267–278.
40. Northcote R, Canning GP, Ballantyne D. Electrocardiographic findings in male veteran endurance athletes. *Br Heart J* 1989;**61**:155–160.
41. Balady GJ, Cadigan JB, Ryan TJ. Electrocardiogram of the athlete: An analysis of 289 professional football players. *Am J Cardiol* 1984;**53**:1339–1343.
42. Stein R, Medeiros CM, Rosito GA, Zimmerman LI, Ribeiro JP. Intrinsic sinus and atrioventricular node electrophysiologic adaptations in endurance athletes. *J Am Coll Cardiol* 2002;**39**:1033–1038.
43. Venerando A, Rulli V. Frequency morphology and meaning of the electrocardiographic anomalies found in Olympic marathon runners and walkers. *J Sports Med Phys Fitness* 1964;**4**:135–141.
44. Myetes I, Kaplinsky E, Yahini J, Hanne-Paparo N, Neufeld HN, Wenckenbach AV block: a frequent feature following heavy physical training. *Am Heart J* 1975;**90**:426–430.
45. Zehender M, Meinertz T, Keul J, Just H. ECG variants and cardiac arrhythmias in athletes: clinical relevance and prognostic importance. *Am Heart J* 1990;**119**:1378–1391.
46. Parker B, Londeree B, Cupp G, Dubiel JP. The noninvasive cardiac evaluation of long-distance runners. *Chest* 1978;**73**:376–381.
47. Nakamoto K. Electrocardiograms of 25 marathon runners before and after 100 meter dash. *Jpn Circ J* 1969;**33**:105–126.
48. Douglas PS, O'Toole ML, Hiller DE, Hackney K, Reichel N. Electrocardiographic diagnosis of exercise-induced left ventricular hypertrophy. *Am Heart J* 1988;**116**:784–790.
49. Langdeau JB, Blier L, Turcotte H, O'Hara G, Boulet LP. Electrocardiographic findings in athletes: the prevalence of left ventricular hypertrophy and conduction defects. *Can J Cardiol* 2001;**17**:655–659.
50. Peidro R, Brion G, Angelino A, Mauro S, Guevara E, Gonzalez J, Galizio N, Motta D, Diaz J. Cardiovascular and physical capacity findings in Argentine soccer professional players. *Rev Argent Cardiol* 2004;**72**:263–269.
51. Moore EN, Boineau JP, Patterson DF. Incomplete right bundle branch block: an electrocardiographic enigma and possible misnomer. *Circulation* 1971;**44**:678–687.
52. Fagard R, Aubert A, Lysens J, Staessen J, Vanhees L, Amery A. Noninvasive assessment of seasonal variations in cardiac structure and function in cyclists. *Circulation* 1983;**97**:896–901.
53. Corrado D, Basso C, Thiene G. Arrhythmogenic right ventricular cardiomyopathy: diagnosis, prognosis, and treatment. *Heart* 2000;**83**:588–595.
54. Gussak I, Bjerregaard P, Egan TM, Chaitman BR. ECG phenomenon called the J wave. History, pathophysiology, and clinical significance. *J Electrocardiol* 1995;**28**:49–58.
55. Willems JL, Robles De Medina EO, Bernard R, Coumel P, Fisch C, Krikler D, Mazur NA, Meijer FL, Mogensen L, Moret P. Criteria for intraventricular conduction disturbances and pre-excitation. *J Am Coll Cardiol* 1985;**5**:1261–1275.
56. Brady WJ, Chan TC. Electrocardiographic manifestations: benign early repolarization. *J Emerg Med* 1999;**17**:473–478.
57. Brady WJ. Benign early repolarization: electrocardiographic manifestations and differentiation from other ST segment elevation syndromes. *Am J Emerg Med* 1998;**16**:592–597.
58. Gussak I, Antzelevitch C. Early repolarization syndrome: clinical characteristics and possible cellular and ionic mechanisms. *J Electrocardiol* 2000;**33**:299–309.
59. Boineau JP. The early repolarization variant—an electrocardiographic enigma with both QRS and JSTT anomalies. *J Electrocardiol* 2007;**40**:3e1–3e10.
60. Gibbons L, Cooper K, Martin R, Pollock M. Medical examination and electrocardiographic analysis of elite distance runners. *Ann N Y Acad Sci* 1977;**301**:283–296.
61. Bianco M, Bria S, Gianfelici A, Sanna N, Palmieri V, Zeppilli P. Does early repolarization in the athlete have analogies with the Brugada syndrome? *Eur Heart J* 2001;**22**:504–510.
62. Corrado D, Pelliccia A, Antzelevitch C, Leoni L, Schiavon M, Buja G, Maron BJ, Thiene G, Basso C. ST segment elevation and sudden death in the athlete. In: Antzelevitch C (ed.), *The Brugada Syndrome: from Bench to Bedside*. Oxford: Blackwell Futura; 2005. p.119–129.
63. Haïssaguerre M, Derval N, Sacher F, Jesel L, Deisenhofer I, de Roy L, Pasquie JL, Nogami A, Babuty D, Yli-Mayry S, De Chillou C, Scanu P, Mabo P, Matsuo S, Probst V, Le Scouarnec S, Defaye P, Schlaepfer J, Rostock T, Lacroix D, Lamaison D, Lavergne T, Atzawa Y, Englund A, Anselme F, O'Neill M, Hocini M, Lim KT, Knecht S, Veenhuizen GD, Bordachar P, Chauvin M, Jais P, Coureau G, Chene G, Klein GJ, Clémenty J. Sudden cardiac arrest associated with early repolarization. *N Engl J Med* 2008;**358**:2016–2023.
64. Turrini P, Corrado D, Basso C, Nava A, Bauce B, Thiene G. Dispersion of ventricular depolarization-repolarization: a noninvasive marker for risk stratification in arrhythmogenic right ventricular cardiomyopathy. *Circulation* 2001;**103**:3075–3080.
65. Nasir K, Bomma C, Tandri H, Roguin A, Dalal D, Prakasa K, Tichnell C, James C, Spevak PJ, Marcus F, Calkins H. Electrocardiographic features of arrhythmogenic right ventricular dysplasia/cardiomyopathy according to disease severity; a need to broaden diagnostic criteria. *Circulation* 2004;**110**:1527–1534.
66. Corrado D, Migliore F, Bevilacqua M, Basso C, Thiene G. Sudden cardiac death in athletes. Can it be prevented by screening? *Herz* 2009;**34**:259–266.
67. Corrado D, Pelliccia A, Bjornstad HH, Vanhees L, Biffi A, Borjesson M, Panhuyzen-Goedkoop N, Deligiannis A, Solberg E, Dugmore D, Mellwig KP, Assanelli D, Delise P, van-Buuren F, Anastasakis A, Heidbuchel H, Hoffmann E, Fagard R, Priori SG, Basso C, Arbustini E, Blomstrom-Lundqvist C, McKenna WJ, Thiene G. Cardiovascular pre-participation screening of young competitive athletes for prevention of sudden death: proposal for a common European protocol. Consensus Statement of the Study Group of Sport Cardiology of the Working Group of Cardiac Rehabilitation and Exercise Physiology and the Working Group of Myocardial and Pericardial Diseases of the European Society of Cardiology. *Eur Heart J* 2005;**26**:516–524.
68. Corrado D, Michieli P, Basso C, Schiavon M, Thiene G. How to screen athletes for cardiovascular diseases. *Cardiol Clin* 2007;**25**:391–397.

69. Corrado D, Thiene G. Protagonist: routine screening of all athletes prior to participation in competitive sports should be mandatory to prevent sudden cardiac death. *Heart Rhythm* 2007;**4**:520–524.
70. Ryan MP, Cleland JGF, French JA, Joshi J, Choudhury L, Chojnowska L, Michalak E, al-Mahdawi S, Nihoyannopoulos P, Oakley CM. The standard electrocardiogram as a screening test for hypertrophic cardiomyopathy. *Am J Cardiol* 1995;**76**:689–694.
71. Melacini P, Fasoli G, Canciani B, Buja G, Mammola C, Volta SD. Hypertrophic cardiomyopathy: Two-dimensional echocardiographic score versus clinical and electrocardiographic findings. *Clin Cardiol* 1989;**12**:443–452.
72. Melacini P, Cianfrocca C, Calore C, Di Paolo F, Quattrini F, Pelliccia F, Sharma S, McKenna WJ, Maron BJ, Pelliccia A, Corrado D. Marginal overlap between electrocardiographic abnormalities in patients with hypertrophic cardiomyopathy and trained athletes: Implications for preparticipation screening. *Circulation* 2007;**116**:765. [abstract 3390].
73. Somauroo JD, Pyatt JR, Jackson M, Perry RA, Ramsdale DR. An echocardiographic assessment of cardiac morphology and common ECG findings in teenage professional soccer players: reference ranges for use in screening. *Heart* 2001;**85**:649–665.
74. Pelliccia A, Di Paolo FM, Quattrini FM, Basso C, Culasso F, Popoli G, De Luca R, Spataro A, Biffi A, Thiene G, Maron BJ. Outcomes in athletes with marked ECG repolarization abnormalities. *N Engl J Med* 2008;**358**:152–161.
75. Corrado D, Michieli P, Schiavon M, Bauce B, Basso C, Nava A, Thiene G. Prevalence and clinical significance of right precordial T-wave inversion at electrocardiographic preparticipation screening: a prospective study on 3086 young competitive athletes. *Circulation* 2007;**116**:765. [Abstract 3392].
76. Papadakis M, Basavarajiah S, Rawlins J, Edwards C, Makan J, Firooz S, Carby L, Sharma S. Prevalence and significance of T-wave inversions in predominantly Caucasian adolescent athletes. *Eur Heart J* 2009; (Epub ahead of print).
77. McKenna WJ, Spirito P, Desnos M, Dubourg O, Komajda M. Experience from clinical genetics in hypertrophic cardiomyopathy: proposal for new diagnostic criteria in adult members of affected families. *Heart* 1997;**77**:130–132.
78. Kreger BE, Anderson KM, Kannel WB. Prevalence of intraventricular block in the general population: The Framingham Study. *Am Heart J* 1989;**117**:903–910.
79. Agarwal AK, Venugopalan P. Right bundle branch block: varying electrocardiographic patterns. Aetiological correlation, mechanisms and electrophysiology. *Int J Cardiol* **71**:33–39.
80. Hadarson T, Arnason A, Eliasson GJ, Pálsson K, Eyjólfsson K, Sigfússon N. Left bundle branch block: prevalence, incidence, follow-up and outcome. *Eur Heart J* 1987;**8**:1075–1079.
81. Elizari MV, Acunzo RS, Ferreiro M. Hemiblocks revisited. *Circulation* 2007;**115**:1154–1163.
82. Rabkin SW, Mathewson FAL, Tate RB. The natural history of right bundle branch block and frontal plane QRS axis in apparently healthy men. *Chest* 1981;**2**:191–196.
83. Rabkin SW, Mathewson FA, Tate RB. Natural history of left bundle-branch block. *Br Heart J* 1980;**43**:164–169.
84. Kyndt F, Probst V, Potet F, Demolombe S, Chevallier JC, Baro I, Moisan JP, Boisseau P, Schott JJ, Escande D, Le Marec H. Novel SCN5A mutation leading either to isolated cardiac conduction defect or Brugada syndrome in a large French family. *Circulation* 2001;**104**:3081–3086.
85. Surawicz B, Childers R, Deal BJ, Gettes LS. AHA/ACCF/HRS Recommendations for the standardization and interpretation of the ECG: Part III: intraventricular conduction disturbances. *J Am Coll Cardiol* 2009;**53**:976–981.
86. Hiss RG, Lamb LE. Electrocardiographic findings in 122 043 individuals. *Circulation* 1962;**25**:947–961.
87. Klein GJ, Bashore TM, Sellers TD, Pritchett EL, Smith WM, Gallagher JJ. Ventricular fibrillation in the Wolff–Parkinson–White syndrome. *N Engl J Med* 1979;**301**:1080–1085.
88. Munger TM, Packer DL, Hammill SC, Feldman BJ, Bailey KR, Ballard DJ, Holmes DR Jr, Gersh BJ. A population study of the natural history of Wolff–Parkinson–White syndrome in Olmsted County, Minnesota, 1953–1989. *Circulation* 1993;**87**:866–873.
89. Sorbo MD, Buja GF, Miorelli M, Nistri S, Perrone C, Manca S, Grasso F, Giordano GM, Nava A. The prevalence of the Wolff–Parkinson–White syndrome in a population of 116,542 young males. *G Ital Cardiol* 1995;**25**:681–687.
90. Sano S, Komori S, Amano T, Kohno I, Ishihara T, Sawanobori T, Ijiri H, Tamura K. Prevalence of ventricular preexcitation in Japanese school children. *Heart* 1998;**79**:374–378.
91. Gollob MH, Green MS, Tang AS, Gollob T, Karibe A, Ali Hassan AS, Ahmad F, Lozado R, Shah G, Fananapazir L, Bachinski LL, Roberts R. Identification of a gene responsible for familial Wolff–Parkinson–White syndrome. *N Engl J Med* 2001;**344**:1823–1831.
92. Murphy RT, Mogensen J, McGarry K, Bahl A, Evans A, Osman E, Syrris P, Gorman G, Farrell M, Holton JL, Hanna MG, Hughes S, Elliott PM, Macrae CA, McKenna WJ. Adenosine monophosphate-activated protein kinase disease mimicks hypertrophic cardiomyopathy and Wolff–Parkinson–White syndrome: natural history. *J Am Coll Cardiol* 2005;**45**:922–930.
93. Napolitano C, Bloise R, Priori SG. Long QT syndrome and short QT syndrome: how to make correct diagnosis and what about eligibility for sports activity. *J Cardio Med* 2006;**7**:250–256.
94. Kapetanopoulos A, Kluger J, Maron BJ, Thompson PD. The congenital long QT syndrome and implications for young athletes. *Med Sci Sports Exerc* 2006;**38**:816–825.
95. Zipes DP, Ackerman MJ, Mark Estes, III NA, Grant AO, Myerburg RJ, Van Hare G. Task Force 7: Arrhythmias (36th Bethesda Conference). *J Am Coll Cardiol* 2005;**45**:1354–1363.
96. Basavarajiah S, Wilson M, Whyte G, Shah A, Behr E, Sharma S. Prevalence and significance of an isolated long QT interval in elite athletes. *Eur Heart J* 2007;**28**:2944–2949.
97. Rautaharju PM, Surawicz B, Gettes LS. AHA/ACCF/HRS Recommendations for the standardization and interpretation of the ECG: Part IV: the ST segment, T and U waves, and the QT interval. *J Am Coll Cardiol* 2009;**53**:982–991.
98. Schwartz PJ, Moss AJ, Michael Vincent GM, Crampton RS. Diagnostic criteria for the long QT syndrome—an update. *Circulation* 1993;**88**:782–784.
99. Schwartz PJ, Spazzolini C, Crotti L, Bathen J, Armlie JP, Timothy K, Shkolnikova M, Berul CI, Bitner-Glindzic M, Toivonen L, Horie M, Schulze-Bahr E, Denjoy I. The Jervell and Lange–Nielsen syndrome: natural history, molecular basis, and clinical outcome. *Circulation* 2006;**113**:783–790.
100. Zhang L, Timothy KW, Vincent GM, Lehmann MH, Fox J, Giuli LC, Shen J, Splawski I, Priori SG, Compton SJ, Yanowitz F, Benhorin J, Moss AJ, Schwartz PJ, Robinson JL, Wang Q, Zareba W, Keating MT, Towbin JA, Napolitano C, Medina A. Spectrum of ST T-wave patterns and repolarization parameters in congenital long-QT syndrome: ECG findings identify genotypes. *Circulation* 2000;**102**:2849–2855.
101. Maury P, Extramiana F, Sbragia P, Giustetto C, Schimpf R, Duparc A, Wolpert C, Denjoy I, Delay M, Borggrefe M, Gaita F. Short QT syndrome. Update on a recent entity. *Arch Cardiovasc Dis* 2008;**101**:779–786.
102. Gaita F, Giustetto C, Bianchi F, Wolpert C, Schimpf R, Riccardi R, Grossi S, Richiardi E, Borggrefe M. Short QT syndrome: a familial cause of sudden death. *Circulation* 2003;**103**:965–970.
103. Schimpf R, Borggrefe M, Wolpert C. Clinical and molecular genetics of the short QT syndrome. *Curr Opin Cardiol* 2008;**23**:192–198.
104. Bigi MA, Aslani A, Aslani A. Short QT interval: a novel predictor of androgen abuse in strength trained athletes. *Ann Noninvasive Electrocardiol* 2009;**14**:35–39.
105. Wilde AA, Antzelevitch C, Borggrefe M, Brugada J, Brugada R, Brugada P, Corrado D, Hauer RN, Kass RS, Nademanee K, Priori SG, Towbin JA Study Group on the Molecular Basis of Arrhythmias of the European Society of Cardiology. Proposed diagnostic criteria for the Brugada syndrome. *Eur Heart J* 2002;**23**:1648–1654.
106. Antzelevitch C, Brugada P, Borggrefe M, Brugada J, Brugada R, Corrado D, Gussak I, LeMarec H, Nademanee K, Perez Riera AR, Shimizu W, Schulze-Bahr E, Tan H, Wilde A. Brugada syndrome: report of the second consensus conference. *Heart Rhythm* 2005;**2**:429–440.
107. Medrano GA, De Micheli A. Contribution experimental al diagnostico de los bloqueos fasciculares derechos. *Arch Inst Cardiol Mex* 1975;**45**:704–713.
108. Junttila MJ, Gonzalez M, Lizotte E, Benito B, Vernoooy K, Sarkozy A, Huikuri HV, Brugada P, Brugada J, Brugada R. Induced Brugada-type electrocardiogram, a sign for imminent malignant arrhythmias. *Circulation* 2008;**8**:1890–1893.